

· 基础研究 ·

人工智能 THA 术前规划的尸体验证研究[△]

郑勇强, 王泽峰, 方阳振, 刘晓峰, 张鸿鹏, 张金山*

[晋江市医院(上海市第六人民医院福建医院)骨科, 福建晋江 362200]

摘要: [目的] 验证“肩对肩”解剖标记定位法在大体标本全髋关节置换(total hip arthroplasty, THA)中恢复下肢长度的作用。[方法] 在4具尸体行闭孔外肌肌腱止点的下为截骨标志的“肩对肩”THA, 测量术后骨盆正位片下肢长度、尖肩距、截骨距、股骨头旋转中心(center of rotation, COR)纵向及水平偏移度、髋臼外展角及前倾角, 并与人工智能辅助规划系统(AI-HIP)进行验证。[结果] 4具尸体术后均达到双下肢等长。术后影像学测量与AIHIP规划的尖肩距、截骨距、股骨头旋转中心纵向偏移度及旋转中心水平偏移度比较差异均无统计学意义($P>0.05$); 术后影像学测量的髋臼外展角[(32.5±3.1)° vs (41.3±2.5)°, $P=0.005$]显著小于AIHIP规划的髋臼外展角, 术后影像学测量的髋臼前倾角[(25.3±9.4)° vs (18.8±2.5)°, $P=0.030$]显著大于AIHIP规划的髋臼前倾角。术中测量的尖肩距显著大于术后影像测量[(26.3±2.6) mm vs (15.5±1.5) mm, $P<0.001$]和术前AIHIP规划[(26.3±2.6) mm vs (17.0±2.2) mm, $P<0.001$]。[结论] 尸体手术对AIHIP的验证表明, 股骨侧“肩对肩”解剖标记定位法能够保证股骨侧假体准确置入合适位置, 有效恢复下肢长度, 尽管不同时间点测量的部分参数有差异。

关键词: 全髋关节置换, 尸体手术, 人工智能规划, 解剖标志, 测量**中图分类号:** R688.4 **文献标志码:** A **文章编号:** 1005-8478(2024)16-1497-05

Artificial intelligence total hip arthroplasty preoperative planning verified in cadavers // ZHENG Yong-qiang, WANG Ze-feng, FANG Yang-zhen, LIU Xiao-feng, ZHANG Hong-peng, ZHANG Jin-shan. Department of Orthopedics, Jinjiang Hospital (Fujian Hospital of Shanghai Sixth People's Hospital), Jinjiang 362200, China

Abstract: [Objective] To verify the effect of "shoulder-to-shoulder" anatomical marker localization in restoring lower limb length during total hip arthroplasty (THA). [Methods] "Shoulder-to-shoulder" THA was performed in 4 cadavers based on insertion obturator externus as the "shoulder" of the femur for osteotomy. The length of lower limb, tip-shoulder distance, osteotomy distance, longitudinal and horizontal deviation of center of rotation (COR) of femoral head, acetabular abduction angle and acetabular anteversion angle were measured, and verified with the artificial intelligence hip (AIHIP). [Results] All the 4 cadavers got equal length of bilateral lower limbs after operation. There were no statistically significant differences in tip-shoulder distance, osteotomy distance, longitudinal and horizontal deviations of femoral head COR between the postoperative imaging measurement and the preoperative AIHIP planning ($P>0.05$). However, the acetabular abduction angle measured by postoperative image was significantly lower than that planned by AIHIP [(32.5±3.1)° vs (41.3±2.5)°, $P=0.005$], while the acetabular anteversion measured postoperatively were significantly greater than that planned by AIHIP [(25.3±9.4)° vs (18.8±2.5)°, $P=0.030$]. In addition, The tip-shoulder distance measured intraoperatively was significantly greater than that measured by postoperative imaging [(26.3±2.6) mm vs (15.5±1.5) mm, $P<0.001$], and preoperative AIHIP planning [(26.3±2.6) mm vs (17.0±2.2) mm, $P<0.001$]. [Conclusion] The validation of AIHIP after cadaveric surgery shows that the "shoulder-to-shoulder" as anatomic marker for femoral stem placement does ensure the accurate placement and effectively restore the lower limb length, although some parameters measured at different time points are different.

Key words: total hip arthroplasty, cadaveric surgery, artificial intelligence planning, anatomical markers, measurement

术后双下肢等长与否是决定全髋关节置换(total hip arthroplasty, THA)术后患者满意度和功能的重要参数之一^[1, 2]。尽管有详细的术前计划及模板规

划^[3, 4]、多种多样的术中测试方法^[5, 6], 甚至导航技术和机器人辅助手术^[7, 8], 但目前没有一种方法被普遍接受^[9]。因此, 大多数手术医生仍然依赖于术前模

DOI:10.20184/j.cnki.Issn1005-8478.100681

△基金项目: 泉州市科技计划项目(编号:2020N079s); 福建中医药大学校管科研课题项目(编号:XB2022149)**作者简介:** 郑勇强, 副主任医师, 研究方向: 脊柱、骨病及损伤, (电子信箱)yongqiang_zheng@163.com*** 通信作者:** 张金山, (电话)0595-85681738, (电子信箱)zhangjinshan196@sina.com

板、术中标记和对腿长的整体感觉等多种方法相结合来预防THA术后双下肢不等长。转子窝的最低点(闭孔外肌肌腱止点)是一个重要的解剖标记^[10],其作为THA术前模板规划、术中操作参考的标记点在股骨假体的置入及预防术后双下肢不等长的有效性已得到临床初步验证^[11, 12]。本研究将对4具大体标本进行解剖,显露转子窝最低点(即股骨的“肩”)并通过该标记定位指导髋关节置换手术,术后与计算机人工智能辅助手术规划比较,验证此方法的可行性。

1 材料与方法

1.1 尸体来源

选取4具经福尔马林防腐处理的成人大体髋关节标本(年龄不详)作为研究对象。标本由华侨大学医学院解剖教研室提供,获得医学伦理委员会讨论通过(伦理审批号:jjssyyxll-2020022)。对4具大体标本进行骨盆正位X线片拍摄及CT扫描,排除髋关节结构的病变或异常。由同一组医师采用后外侧入路对4具成人大体股骨近端进行解剖观察,行单侧全髋关节置换并测量相关参数。术后拍摄骨盆正位X线片并测量相关参数。

1.2 术前AIHIP规划

将骨盆薄层CT扫描数据以DICOM格式输出储存,导入人工智能三维规划软件系统(AIHIP系统;北京长木谷医疗科技有限公司),智能测算髋臼及股骨假体最佳位置放置,计算术前股骨偏心距、联合偏心距、下肢腿长差等,规划出最优的结果,提供理想化的假体类型,组件尺寸参照模型^[13]。

1.3 尸体手术

由同一主刀医师采用后外侧入路手术(图1a),显露附着于股骨转子间窝的髋关节外旋肌,清除附着于转子窝的软组织,显露“转子窝”,截骨前用标记笔标注股骨的“肩”,也就是闭孔外肌肌腱下缘股骨附着点处即转子窝的最低点(图1b);截骨模板近端置于标记股骨的“肩”处并在股骨颈上标识截骨线,电动摆锯进行截骨(图1c);取出股骨头,显露髋臼,原位安装髋臼假体。显露股骨侧,逐一锉髓腔,髓腔锉的“肩”到达标记股骨“肩”水平并且髓腔锉在髓腔内没有旋转且继续敲打不再下沉,置入与最后确定的髓腔锉大小一致的股骨柄假体,并确保置入假体的“肩”(图1d)与股骨“肩”相吻合(图1e);安装AIHIP规划颈长的球头,逐层缝合切口(图1f)。

1.4 测量方法

术前规划:术前AIHIP系统规划置入假体后的相关评价指标,数据由北京长木谷医疗科技有限公司提供。

术中尸体测量:尸体解剖并行THA试验,手术过程中直接采用尺子测量尖肩距,即大转子尖部至股骨柄“肩”部的垂直距离。

术后影像学测量:(1)放大倍率计算:放大倍率=术后骨盆正位X线片球头直径/术中实际使用球头直径,将各测量的数据除以放大倍率得到实际值;(2)下肢长度测量:小转子内缘顶点到两侧泪滴下缘连线的垂直距离代表下肢长度;(3)尖-肩距测量:大转子尖部至股骨柄“肩”部的垂直距离;(4)截骨距测量:小转子上缘至截骨平面的垂直距离;(5)股骨头旋转中心(center of rotation, COR)纵向偏移度:股骨头旋转中心到两侧泪滴下缘连线的垂直距离;(6)股骨头COR水平偏移度:股骨头旋转中心到股骨干轴线的垂直距离;(7)髋臼外展角测量:髋臼假体长轴与两侧泪滴下缘连线的夹角;(8)髋臼前倾角。

1.5 统计学方法

采用SPSS 26.0软件进行统计学分析。计量资料以 $\bar{x} \pm s$ 表示。双侧下肢长度允许差距为 ± 5 mm内^[14],采用双单侧检验(Two one-sided test, TOST);不同测量采用配对T检验。 $P < 0.05$ 为差异有统计学意义。

2 结果

2.1 术后双侧下肢长度测量比较

术后影像学测量的双侧下肢长度差TOST检验均拒绝上下界值假设($P_{\text{差值} \leq -5 \text{ mm}} < 0.05$, $P_{\text{差值} \geq 5 \text{ mm}} < 0.05$),表明术后下肢等长成立。

2.2 术后影像学及AIHIP校正规划参数比较

术后影像学及AIHIP规划的参数结果与比较见表1,两次测量的尖肩距、截骨距、股骨头旋转中心纵向偏移度及旋转中心水平偏移度比较差异均无统计学意义($P > 0.05$);术后影像学测量的髋臼外展角显著小于AIHIP规划的髋臼外展角($P < 0.05$),术后影像学测量的髋臼前倾角显著大于AIHIP规划的髋臼前倾角($P < 0.05$)。

2.3 术中测量与术后影像学和AIHIP规划的尖肩距比较

4具尸体术中、术后影像学及AIHIP规划置入假体后的尖肩距分别为(26.3 \pm 2.6) mm、(15.5 \pm 1.5)

mm、 (17.0 ± 2.2) mm，后两者与前者差值分别为 (10.8 ± 4.1) mm、 (9.3 ± 4.6) mm，差异均有统计学意

义 ($P < 0.001$)，术中测量的尖肩距显著大于术后影像学测量及 AIHIP 校正规划的尖肩距。

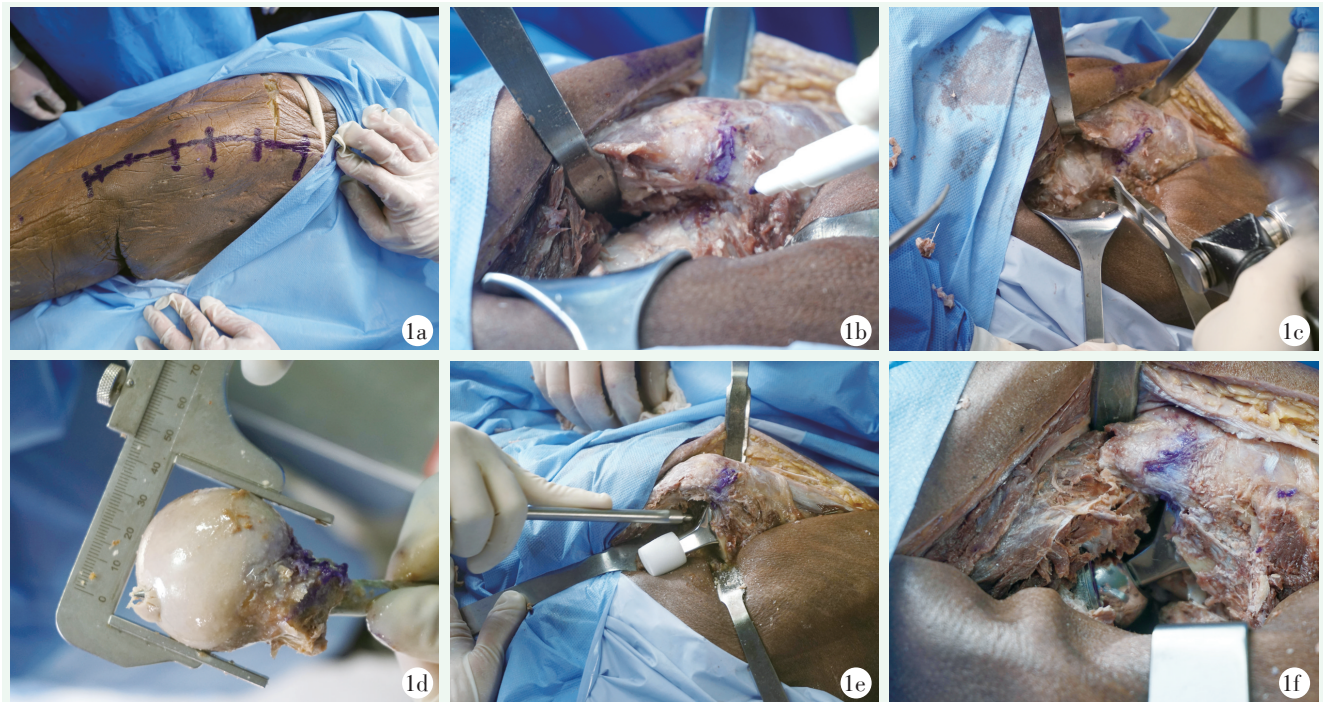


图 1. 尸体标本采用“肩对肩”人工解剖标记法行全髋关节置换手术。1a: 行髋后外侧入路切口；1b: 标记股骨的“肩”，即为闭孔外肌腱止点下缘即转子窝最低点的水平；1c: 截骨后再次确认“肩”；1d: 测量股骨头最大直径；1e: 将假体的“肩”打至股骨的“肩”水平，完成“肩对肩”；1f: 安装球头，完成假体置入。

Figure 1. Total hip arthroplasty based on "shoulder-to-shoulder" anatomical markers in cadaver. 1a: Posterolateral approach was made; 1b: Mark the "shoulder" of the femur, that is, the lowest edge of the obturator externus tendon insertion in the trochanteric fossa; 1c: Confirm "shoulder" again after osteotomy; 1d: Measuring the maximum diameter of the femoral head; 1e: Fit the "shoulder" of the femoral component to the "shoulder" level of the femur to complete the "shoulder-to-shoulder" femoral stem placement; 1f: Install the ball head and complete the prosthesis implantation.

表 1. 4 具尸体术后影像测量结果及 AIHIP 规划参数 ($\bar{x} \pm s$) 与比较

Table 1. Comparison of parameters between postoperative imaging and AIHIP planning in the 4 cadavers ($\bar{x} \pm s$)

指标	术后影像学测量	术前 AIHIP 规划	两者差值	P 值
尖肩距 (mm)	15.5 ± 1.5	17.0 ± 2.2	-1.5 ± 1.5	0.135
截骨距 (mm)	8.4 ± 2.3	7.5 ± 2.7	0.9 ± 1.0	0.174
COR 纵向偏移 (mm)	12.5 ± 1.9	0.5 ± 2.0	0.5 ± 2.0	0.667
COR 水平偏移 (mm)	34.8 ± 5.9	32.8 ± 6.4	2.0 ± 2.9	0.660
髋臼外展角 ($^{\circ}$)	32.5 ± 3.1	41.3 ± 2.5	8.8 ± 3.3	0.005
髋臼前倾角 ($^{\circ}$)	25.3 ± 9.4	18.8 ± 2.5	-6.5 ± 11.2	0.030

3 讨论

转子窝位于股骨大转子尖端内后侧的凹陷处，作为闭孔外肌的止点，是外科手术尤其是髋关节置换术中的一个重要解剖标志^[15]。Vles 等^[16]通过解剖和影像学研究确认了闭孔外肌在转子窝的位置，并将其作

为髋关节置换术前规划和术中参考的重要标志。Rüdiger 等^[17]对 200 例成年人的 CT 分析发现，闭孔外肌腱止点在所有 CT 扫描中均可见，因此该点可用作手术规划及术中操作的参考。

大体解剖发现股骨“肩”的位置对于髓腔锉的标记和股骨柄假体植入深度具有重要指导意义，使股骨柄假体位置达到原有的解剖位置，恢复原有的功能解

剖, 实现对下肢长度股骨侧影响因素的控制。基于数字影像的术前规划对 THA 假体型号的预测、假体位置安放及双下肢等长重建更加精准, 能够促进早期功能恢复^[18, 19]。本研究表明, 采用上述精准规划后的 THA 手术基本不改变下肢长度, 与术前规划的下肢长度结果一致, 可达到 AIHIP 规划的理想状态。

术中测量尖-肩距显著大于术后影像学及 AIHIP 规划置入假体后的尖肩距, 分析原因考虑系大转子尖部的骨膜及其他软组织覆盖所造成, 因此术中测量值通常较大, 提示术中假体置入深度如参考 AIHIP 规划的尖肩距时, 需兼顾软组织厚度。本研究结果显示, 术后影像学测量与 AIHIP 规划置入假体后的尖-肩距差异无统计学意义, 说明在无软组织干扰的影像学层面上进行对比, 选取股骨侧的“肩”作为解剖标记可指导股骨侧假体位置达到 AIHIP 规划的理想状态。

研究表明, 准确的股骨侧精准截骨有助于减少全髋关节置换术后的双下肢长度差异。Kim 等^[20]研究了不同解剖标记对截骨水平确定性的影响, 不建议使用小转子顶点作为截骨距截骨高度的参考。本研究选择股骨侧的“肩”作为截骨解剖标记, 直接按照截骨模板的引导进行截骨, 并不考虑截骨距预留长短, 如 Corail 的截骨模板为 45°, 而 Summit 的截骨模板为 50°, 两种最终预留的截骨距不同。本研究 4 例大体标本均应用 Corail 假体的 45°截骨模板, 术后影像学及 AIHIP 规划的截骨距的一致性可能因统一使用 Corail 模板, 也可能是因为样本量小 (4 例) 导致偶然的结果。

本研究显示, THA 术后与 AIHIP 规划的旋转中心纵向偏移无显著差异, 说明对于髋臼侧不存在解剖变异或骨质破坏的情况下, 在 THA 中髋臼侧假体的原位安放不会明显改变下肢长度。然而, 4 例受福尔马林影响的大体标本存在畸形及体位影响, 尸体手术操作过程中髋臼的前倾及外展角度把控偏差较大, 无法放置在 AIHIP 系统规划的理想髋臼假体位置。此外, 股骨头假体颈部长短的变化对下肢长度的影响有限, 其长度变化在纵向上仅有 2.5 mm^[11]。

本研究的不足: (1) 由于标本受福尔马林浸泡, 下肢出现不同程度畸形及体位影响, 难以直接拍摄到标准骨盆正位 X 线片; (2) AIHIP 系统允许存在 5 mm 内的下肢不等长偏倚, 参照对象并不是绝对理想化; (3) 样本量不足; (4) 只探讨后外侧入路的应用, 相对局限。

参考文献

- [1] Konyves A, Bannister GC. The importance of leg length discrepancy after total hip arthroplasty [J]. *J Bone Joint Surg Br*, 2005, 87 (2): 155-157. DOI: 10.1302/0301-620x.87b2.14878.
- [2] Innmann MM, Maier MW, Streit MR, et al. Additive influence of hip offset and leg length reconstruction on postoperative improvement in clinical outcome after total hip arthroplasty [J]. *J Arthroplasty*, 2018, 33 (1): 156-161. DOI: 10.1016/j.arth.2017.08.007.
- [3] Lakstein D, Bachar I, Debi R, et al. Radiographic templating of total hip arthroplasty for femoral neck fractures [J]. *Int Orthop*, 2017, 41 (4): 831-836. DOI: 10.1007/s00264-016-3235-y.
- [4] Vigdorchik JM, Sharma AK, Jerabek SA, et al. Templating for total hip arthroplasty in the modern age [J]. *J Am Acad Orthop Surg*, 2021, 29 (5): e208-e216. DOI: 10.5435/JAAOS-D-20-00693.
- [5] 袁涛, 翁文杰. 全髋关节置换术下肢不等长的术中对策 [J]. *中国矫形外科杂志*, 2009, 17 (7): 548-549.
Yuan T, Weng WJ. Intraoperative strategies for length discrepancy of lower limbs in total hip replacement surgery [J]. *Orthopedic Journal of China*, 2009, 17 (7): 548-549.
- [6] Stathopoulos IP, Andrianopoulos N, Paschaloglou D, et al. A new method for intraoperative assessment of leg length, sizing and placement of the components in total hip replacement [J]. *Eur J Orthop Surg Traumatol*, 2020, 30 (4): 689-694. DOI: 10.1007/s00590-019-02621-1.
- [7] Huo J, Huang G, Han D, et al. Value of 3D preoperative planning for primary total hip arthroplasty based on artificial intelligence technology [J]. *J Orthop Surg Res*, 2021, 16 (1): 156. DOI: 10.1186/s13018-021-02294-9.
- [8] 丁冉, 王淇, 刘焯, 等. 人工智能三维术前规划在全髋关节置换术中的应用和准确性分析 [J]. *生物骨科材料与临床研究*, 2022, 19 (2): 33-38. DOI: 10.3969/j.issn.1672-5972.2022.02.007.
Ding R, Wang Q, Liu Y, et al. Application and accuracy analysis of artificial intelligence three-dimensional preoperative planning in total hip replacement [J]. *Orthopaedic Biomechanics Materials and Clinical Study*, 2022, 19 (2): 33-38. DOI: 10.3969/j.issn.1672-5972.2022.02.007.
- [9] Kayani B, Pietrzak J, Hossain FS, et al. Prevention of limb length discrepancy in total hip arthroplasty [J]. *Br J Hosp Med*, 2017, 78 (7): 385-390. DOI: 10.12968/hmed.2017.78.7.385.
- [10] Georgiadis GM, Olexa TA, Ebraheim NA. Entry sites for antegrade femoral nailing [J]. *Clin Orthop Relat Res*, 1996, 330 (330): 281-287. DOI: 10.1097/00003086-199609000-00036.
- [11] 张金山, 郑勇强, 林振宇, 等. 股骨颈骨折髋关节置换术中下肢长度测量方法的比较 [J]. *中国骨伤*, 2020, 33 (11): 1012-1016. DOI: 10.12200/j.issn.1003-0034.2020.11.005.
Zhang JS, Zheng YQ, Lin ZY, et al. Comparison of measurement methods of lower limb length in hip arthroplasty for femoral neck fracture [J]. *China Journal of Orthopaedics and Traumatology*, 2020, 33 (11): 1012-1016. DOI: 10.12200/j.issn.1003-0034.2020.11.005.
- [12] Georges V, Anthony EV, Orcun T, et al. Anatomical mapping of

- the external obturator footprint: a study in cadavers with implications for direct anterior THA [J]. *Clin Orthop Relat Res*, 2021, 479 (2): 288-294. DOI: 10.1097/CORR.0000000000001492.
- [13] 吴东, 刘星宇, 张逸凌, 等. 人工智能辅助全髋关节置换术三维规划系统的研发及临床应用研究 [J]. *中国修复重建外科杂志*, 2020, 34 (09): 1077-1084. DOI: 10.7507/1002-1892.202005007.
- Wu D, Liu XY, Zhang YL, et al. Research and application of artificial intelligence based three-dimensional preoperative planning system for total hip arthroplasty [J]. *Chinese Journal of Reparative and Reconstructive Surgery*, 2020, 34 (09): 1077-1084. DOI: 10.7507/1002-1892.202005007.
- [14] Theruvil B, Kapoor V. Surgical treatment of limb-length discrepancy following total hip arthroplasty [J]. *J Bone Joint Surg Am*, 2004, 86 (8): 1829. DOI: 10.2106/00004623-200408000-00039.
- [15] Solomon LB, Lee YC, Callary SA, et al. Anatomy of piriformis, obturator internus and obturator externus: implications for the posterior surgical approach to the hip [J]. *J Bone Joint Surg Br*, 2010, 92 (9): 1317-1324. DOI: 10.1302/0301-620X.92B9.23893.
- [16] Vles G, Meynen A, De MJ, Ghijssels S. The External obturator footprint is a usable, accurate, and reliable landmark for stem depth in direct anterior THA [J]. *Clin Orthop Relat Res*, 2021, 479 (8): 1842-1848. DOI: 10.1097/CORR.0000000000001799.
- [17] Rüdiger HA, Fritz B, Impellizzeri FM, et al. The external obturator footprint as a landmark in total hip arthroplasty through a direct anterior approach: a CT-based analysis [J]. *Hip Int*, 2018, 29 (1): 96-101. DOI: 10.1177/1120700018761320.
- [18] 杨滨, 张克, 袁亮, 等. 三维术前规划在全髋关节置换术中的应用 [J]. *中国矫形外科杂志*, 2022, 30 (7): 653-656. DOI: 10.3977/j.issn.1005-8478.2022.07.16.
- Yang B, Zhang K, Yuan L, et al. Application of three-dimensional preoperative planning in total hip arthroplasty [J]. *Orthopedic Journal of China*, 2022, 30 (7): 653-656. DOI: 10.3977/j.issn.1005-8478.2022.07.16.
- [19] 吴健, 江建平, 冯孝志, 等. 初次全髋关节置换术前数字虚拟手术的意义 [J]. *中国矫形外科杂志*, 2023, 31 (19): 1742-1747. DOI: 10.3977/j.issn.1005-8478.2023.19.03.
- Wu J, Jiang JP, Feng XZ, et al. Significance of digital virtual planning before primary total hip replacement [J]. *Orthopedic Journal of China*, 2023, 31 (19): 1742-1747. DOI: 10.3977/j.issn.1005-8478.2023.19.03.
- [20] Kim JI, Moon NH, Shin WC, et al. Reliable anatomical landmarks for minimizing leg-length discrepancy during hip arthroplasty using the lateral transgluteal approach for femoral neck fracture [J]. *Injury*, 2017, 48 (11): 2548-2554. DOI: 10.1016/j.injury.2017.08.065.

(收稿:2023-09-24 修回:2024-03-20)

(同行评议专家: 江起庭, 付国建)

(本文编辑: 宁桦)

(上接 1496 页)

- [41] Kuwahara W, Sasaki S, Yamamoto R, et al. The effects of robot-assisted gait training combined with non-invasive brain stimulation on lower limb function in patients with stroke and spinal cord injury: A systematic review and meta-analysis [J]. *Front Hum Neurosci*, 2022, 16: 969036. DOI: 10.3389/fnhum.2022.969036.
- [42] Plaza A, Hernandez M, Puyuelo G, et al. Wearable rehabilitation exoskeletons of the lower limb: analysis of versatility and adaptability [J]. *Disabil Rehabil Assist Technol*, 2023, 18 (4): 392-406. DOI: 10.1080/17483107.2020.1858976.

(收稿:2023-07-13 修回:2024-01-17)

(同行评议专家: 陶海荣, 佟磊, 李艳军)

(本文编辑: 宁桦)