

· 临床论著 ·

开放获取

开窗与髓芯减压植骨治疗中期股骨头坏死[△]

查杨晓志, 陈雁雄, 张俊, 连星辉, 孟增东*

[昆明理工大学附属医院(云南省第一人民医院)骨科, 云南昆明 650032]

摘要: [目的] 比较股骨头-颈交界开窗减压打压植骨术与股骨头髓芯减压打压植骨重建棒置入术治疗中期股骨头缺血性坏死(osteonecrosis of the femoral head, ONFH)的临床疗效。[方法] 回顾性分析本院2014年6月—2022年4月收治的100例ONFH患者的临床资料,按照术前医患沟通结果,行开窗(开窗组)与髓芯(髓芯组)减压植骨治疗各50例。比较两组围手术期、随访及影像资料。[结果] 开窗组手术时间[(54.4±7.2) min vs (46.3±6.8) min, $P<0.001$]、切口总长度[(4.2±0.8) cm vs (3.5±0.6) cm, $P<0.001$]、术中失血量[(100.5±12.0) ml vs (50.8±7.4) ml, $P<0.001$]均显著多于髓芯组,但前者的植骨量[(2.5±0.5) g vs (4.3±0.6) g, $P<0.001$]、下地行走时间[(96.0±5.2) d vs (106.3±10.6) d, $P<0.001$]、住院天数[(5.5±0.7) d vs (7.0±1.2) d, $P<0.001$]均显著少于髓芯组。随访时间平均(30.0±3.5)个月,开窗组完全负重活动时间显著早于髓芯组[(180.8±26.5) d vs (200.0±35.0) d, $P=0.003$]。随时间推移,两组术后VAS评分、HHS评分、iHOT-33评分及髋伸-屈、髋内-外旋ROM均显著改善($P<0.05$)。开窗组术后3个月VAS评分[(2.8±0.6) vs (3.1±0.8), $P=0.036$]、HHS评分[(76.7±5.6) vs (72.4±6.5), $P<0.001$]、iHOT-33评分[(64.8±6.0) vs (60.5±5.6), $P<0.001$]均显著优于髓芯组。末次随访时开窗组股骨头生存率的差异无统计学意义[42/50 (84.0%) vs 37/50 (74.0%), $P=0.220$]。21例保髋失败患者中,行翻修髋关节置换术10例(47.6%)。影像方面,与术前相比,术后6个月及末次随访时,两组ARCO分级、Tönnis分期无显著变化($P>0.05$),但是,两组病灶、关节积液征象显著改善($P<0.05$)。相应时间点,两组上述指标比较的差异均无统计学意义($P>0.05$)。[结论] 开窗减压植骨治疗中期ONFH在完全负重活动时间及术后3个月髋关节功能改善上优于髓芯减压植骨。

关键词: 中青年, 股骨头缺血性坏死, 股骨头-颈交界开窗减压打压植骨术, 股骨头髓芯减压打压植骨重建棒置入术
中图分类号: R681.8 **文献标志码:** A **文章编号:** 1005-8478 (2025) 01-0005-07

Fenestration versus core decompression and bone grafting for medium-term femoral head necrosis // ZHA Yang-xiaozhi, CHEN Yan-xiong, ZHANG Jun, LIAN Xing-ye, MENG Zeng-dong. Department of Orthopedics, Kunming University of Science and Technology Affiliated Hospital, The First People's Hospital of Yunnan Province, Kunming, Yunnan 650032, China

Abstract: [Objective] To compare the clinical efficacy of fenestration at femoral head-neck interface for decompression and impacting bone grafting (the FDBG) versus core decompression, and impacting bone grafting with a strut graft (the CDBG) for medium-term osteonecrosis of the femoral head (ONFH). **[Methods]** A retrospective study was conducted on 100 patients who underwent surgical treatment for medium-term ONFH in our hospital from June 2014 to April 2022. According to the preoperative doctor-patient communication, 50 patients received the FDBG, while other 50 patients underwent the CDBG. The perioperative, follow-up and imaging data of the two groups were compared. **[Results]** The FDBG group proved significantly greater than the CDBG group in term of operation time [(54.4±7.2) min vs (46.3±6.8) min, $P<0.001$], total length of incision, [(4.2±0.8) cm vs (3.5±0.6) cm, $P<0.001$], intraoperative blood loss [(100.5±12.0) ml vs (50.8±7.4) ml, $P<0.001$], whereas the former was significantly less than the latter regarding volume of bone graft [(2.5±0.5) g vs (4.3±0.6) g, $P<0.001$], ambulation time [(96.0±5.2) days vs (106.3±10.6) days, $P<0.001$] and hospitalization days [(5.5±0.7) days vs (7.0±1.2) days, $P<0.001$]. All patients in both groups were followed up for a mean of (30.0±3.5) months, and the FDBG group resumed full weight-bearing activity significantly earlier than the CDBG group [(180.8±26.5) days vs (200.0±35.0) days, $P=0.003$]. The VAS score, HHS score, iHOT-33 score, hip extension-flexion range of motion (ROM) and hip internal-external rotation ROM significantly improved in both groups over time ($P<0.05$). The FDBG group was significantly superior to the CDBG group in terms of VAS score [(2.8±0.6) vs (3.1±0.8), $P=0.036$], HHS score [(76.7±5.6) vs (72.4±

DOI:10.20184/j.cnki.issn1005-8478.110357

△基金项目: 云南省卫生健康委员会医学领军人才培养计划项目(编号:L-2018004); 云南省“兴滇英才支持计划”名医专项项目(编号:XDYC-MY-2022-0027); 云南省科技厅科技计划重点研发计划项目(编号:202403AC100003)

作者简介: 查杨晓志, 硕士研究生在读, 研究方向: 骨与关节, (电子信箱)CYxz1988@163.com

* **通信作者:** 孟增东, (电子信箱)menggu7119@vip.sina.com

6.5), $P<0.001$] and iHOT-33 score [(64.8±6.0) vs (60.5±5.6), $P<0.001$] 3 months postoperatively. At the last follow-up, there was no statistically significant difference in the survival rate of the femoral head between the FDBG and CDBG groups [42/50 (84.0%) vs 37/50 (74.0%), $P=0.220$]. Among the 21 patients who failed hip preservation, 10 patients (47.6%) underwent revision hip arthroplasty. As for imaging, there were no significant changes in ARCO grade and Tonnis stage in both groups 6 months after surgery and at the last follow-up, compared with those before operation ($P>0.05$), but the signs of lesions and joint effusion significantly improved between the two groups over time ($P<0.05$). At corresponding time points, there were no statistically significant differences in the abovesaid imaging indicators between the two groups ($P>0.05$). [Conclusion] The fenestration decompression and impacting bone grafting for ONFH is superior to the core decompression bone grafting in time to regain full weight-bearing activity and hip function 3 months after surgery.

Key words: young and middle-aged, avascular necrosis of the femoral head, fenestration at the femoral head-neck junction for decompression and impacting bone grafting, core decompression and impacting bone grafting with a strut graft

股骨头缺血性坏死 (osteonecrosis of the femoral head, ONFH) 多由股骨头血供不足引起, 环境、遗传等多种因素均可致病, 除了致使年轻群体患者的日常生活不便外, 还可能导致下肢残疾等严重后果^[1]。有研究表明, 我国 ONFH 相对原发性髋关节疾病患病率、流行程度低, 但其好发于中青年, 使此年龄段患者备受困扰, 故早期诊断、及时选择合适的治疗方案至关重要^[2]。目前 ONFH 发病机制尚未彻底明了, 但 ONFH 患者特别是中青年患者对体育运动、生活质量要求较高, 多渴望能保全自身原有髋关节, 随着医疗技术不断发展及对股骨头缺血性坏死研究的深入, 保髋治疗日益受到专家及学者的广泛关注^[3, 4]。临床常见保髋手术涉及髓芯减压术、截骨术、带血管腓骨移植术、股骨头-颈开窗减压植骨术等^[5-7], 于控制中青年早中期 ONFH 病情上有一定的作用, 各有优劣。但临床实际中, 对国际骨循环研究协会 (Association Research Circulation Osseous, ARCO) 分期 IIC (股骨头塌陷前期)、IIIA (股骨头塌陷后早期) 股骨头缺血性坏死的 ONFH 患者, 多数医师难以抉择治疗方式, 多依据自身经验, 故加强此类患者临床研究十分必要。何种术式临床效果更优仍存在一定的争议。本研究回顾性分析云南省第一人民医院 2014 年 6 月—2022 年 4 月接受股骨头-颈交界开窗减压打压植骨术或股骨头髓芯减压打压植骨重建棒置入术治疗的中青年 IIC、IIIA 期 ONFH 患者临床资料, 对比两者治疗效果差异, 为此类患者临床手术方式选择提供参考, 报道如下。

1 资料与方法

1.1 纳入与排除标准

纳入标准: (1) 单侧 ONFH 且为 IIC、IIIA 期; (2) 初次行保髋手术; (3) 年龄 20~50 岁; (4) 术后随访至少 1 年, 资料均齐全。

排除标准: (1) 因糖皮质激素依赖性疾病而无法停药者; (2) 合并肝肾等器官衰竭、严重糖尿病/高血压、免疫/血液系统疾病; (3) 术后不能遵医嘱戒烟酒等患者。

1.2 一般资料

回顾性收集云南省第一人民医院 2014 年 6 月—2022 年 4 月收治的 ONFH 100 例患者的临床资料, 根据术前医患沟通结果, 将患者分为两组: 50 例行股骨头-颈交界开窗减压打压植骨术 (开窗组), 50 例行股骨头髓芯减压打压植骨重建棒置入术 (髓芯组)。两组患者一般资料见表 1。两组年龄、性别、BMI、病程、侧别、病因等一般资料的差异均无统计学意义 ($P>0.05$), 本研究经医院伦理委员会批准 (批准号: KHLL2024-KY102), 所有患者均知情同意。

表 1. 两组患者术前一般资料比较
Table 1. Comparison of preoperative general data between the two groups

指标	开窗组 (n=50)	髓芯组 (n=50)	P 值
年龄 (岁, $\bar{x} \pm s$)	35.6±6.2	36.4±6.5	0.530
性别 (例, 男/女)	33/17	35/15	0.668
BMI (kg/m^2 , $\bar{x} \pm s$)	23.4±2.1	22.8±2.6	0.207
病程 (月, $\bar{x} \pm s$)	12.6±3.8	13.0±3.4	0.580
侧别 (例, 左/右)	28/22	30/20	0.685
病因 (例, 激素/酒精/特发)	20/17/13	22/18/10	0.773

1.3 治疗方法

开窗组: 全麻, 选择平卧位, 稍垫高双侧臀部。选择经直接前入路 (direct anterior approach, DAA), 于患者髂前上棘远端 3 cm 稍偏外侧作切口, 长 5 cm 左右, 经阔筋膜张肌及缝匠肌间隙进入, 结扎经过此间隙的旋股外侧动脉升支, 继续逐层分离肌间隙并显露关节囊, 打开关节囊以显露股骨头-颈交界, 并用骨刀制作长宽均 1.5 cm、深 0.5~1.0 cm 的骨窗。透视

下由高速钻头、刮匙将坏死区及部分硬化骨清除，注意需保留 ≥ 0.5 cm 软骨下骨；克氏针钻孔至渗血；彻底清创后冲洗坏死区。自体髂骨松质骨制成颗粒且植入到清创后空腔中，打压夯实，开窗处经由原骨板覆盖，以螺钉固定覆盖骨板，冲洗术野，修复关节囊，逐层缝合切口。

髓芯组：全麻，选择平卧位，稍垫高患侧臀部。于患者大转子下行纵切口，长 3 cm 左右，皮肤等依次切开后将股外侧肌切开，以显露股骨大粗隆外下方，透视下导针置入、空心钻头扩髓到坏死区，铰刀、刮匙处理坏死区，清创后冲洗。同种异体骨条经由生理盐水混合地塞米松浸泡 0.5 h，结合同侧髂骨松质骨及扩髓时产生的泥状碎骨一起植入到清创后空腔中，打压夯实，透视下将合适仿骨重建棒置入，确定位置满意后冲洗、缝合切口。

所有患者手术均由云南省第一人民医院骨科高年资主任医师完成，术后均接受多模式镇痛、抗感染等处理。术后次日指导患者开始股四头肌主动收缩等练习；术后 3 个月内患侧髋关节完全不负重，术后 3~6 个月借助双拐开始部分负重，术后 6~12 个月开始全部负重。

1.4 评价指标

记录围手术期资料，包括手术时间、切口总长度、术中失血量、术中透视次数、植骨量、下地行走时间、切口愈合、住院天数及早期并发症情况。采用完全负重活动时间、疼痛视觉模拟评分 (visual analogue scale, VAS)^[8]、髋关节 Harris 评分 (Harris hip score, HHS)^[9]、国际髋关节预后工具-33 (International Hip Outcome Tool-33, iHOT-33)^[10] 及髋伸-屈/髋内-外旋活动度 (range of motion, ROM) 评价临床效果。评估股骨头生存率，并记录有无翻修手术等不良事件发生。行影像学检查，记录 ARCO 分级、病灶 (骨水肿累及股骨头的面积百分比)、关节积液程度与 Tönnis 评级 (对髋关节退变程度评估)。

1.5 统计学方法

应用 SPSS 28.0 软件分析数据。定量资料满足正态分布时以 $\bar{x} \pm s$ 表示，两组间比较行独立 t 检验，多个时间点比较行重复测量方差分析；定性资料行 χ^2 或连续性校正 χ^2 或 Fisher 精确概率法检验；等级资料行秩和检验。 $P < 0.05$ 为差异有统计学意义。

2 结果

2.1 围手术期资料

两组患者均顺利完成手术，均无切口感染、症状性血栓、股外侧皮神经损伤等并发症出现。开窗组手术时间、切口总长度及术中失血量均显著多于髓芯组 ($P < 0.05$)，而植骨量、下地行走时间、住院天数均显著少于髓芯组 ($P < 0.05$)，两组术中透视次数、切口愈合等级的差异均无统计学意义 ($P > 0.05$)，见表 2。

表 2. 两组患者围手术期资料与比较
Table 2. Perioperative data and comparison between the two groups

指标	开窗组 (n=50)	髓芯组 (n=50)	P 值
手术时间 (min, $\bar{x} \pm s$)	54.4 \pm 7.2	46.3 \pm 6.8	<0.001
切口总长度 (cm, $\bar{x} \pm s$)	4.2 \pm 0.8	3.5 \pm 0.6	<0.001
术中失血量 (ml, $\bar{x} \pm s$)	100.5 \pm 12.0	50.8 \pm 7.4	<0.001
术中透视次数 (次, $\bar{x} \pm s$)	4.0 \pm 0.9	4.2 \pm 1.0	0.296
植骨量 (g, $\bar{x} \pm s$)	2.5 \pm 0.5	4.3 \pm 0.6	<0.001
下地行走时间 (d, $\bar{x} \pm s$)	96.0 \pm 5.2	106.3 \pm 10.6	<0.001
切口愈合 (例, 甲/乙/丙)	50/0/0	50/0/0	-
住院天数 (d, $\bar{x} \pm s$)	5.5 \pm 0.7	7.0 \pm 1.2	<0.001

2.2 随访情况

两组患者均获随访，随访时间 24~56 个月，平均 (30.0 \pm 3.5) 个月。两组随访结果见表 3。开窗组完全负重活动时间显著早于髓芯组 ($P < 0.05$)。随时间推移，两组术后 VAS 评分显著减少 ($P < 0.05$)，HHS 评分、iHOT-33 评分及髋伸-屈/髋内-外旋 ROM 均显著增加 ($P < 0.05$)；术前两组患者上述指标的差异均无统计学意义 ($P > 0.05$)，开窗组术后 3 个月 VAS 评分、HHS 评分、iHOT-33 评分均显著优于髓芯组 ($P < 0.05$)，末次随访两组上述评分的差异均无统计学意义 ($P > 0.05$)；相应时间点，两组髋伸-屈、髋内-外旋 ROM 的差异均无统计学意义 ($P > 0.05$)。末次随访时开窗组股骨头生存 42 例 (84.0%)，髓芯组股骨头生存 37 例 (74.0%)，两组股骨头生存率的差异无统计学意义 ($P = 0.220$)。21 例保髋失败患者中，行翻修髋关节置换术 (total hip arthroplasty, THA) 10 例 (47.6%)。

2.3 影像评估

两组影像资料比较见表 4。与术前相比，术后 6 个月及末次随访时，两组 ARCO 分级、Tönnis 分期无显著变化 ($P > 0.05$)，两组病灶、关节积液征象显著改善 ($P < 0.05$)；同一时间点，两组 ARCO 分级、病灶、关节积液征象与 Tönnis 分期比较的差异均无统计学意义 ($P > 0.05$)。典型病例影像见图 1, 2。

表 3. 两组患者随访资料 ($\bar{x} \pm s$) 与比较
Table 3. Follow-up data of the two groups ($\bar{x} \pm s$) and comparison

指标	时间点	开窗组 (n=50)	髓芯组 (n=50)	P 值
完全负重活动时间 (d)		180.8±26.5	200.0±35.0	0.003
VAS 评分 (分)	术前	5.7±1.0	5.5±0.9	0.296
	术后 3 个月	2.8±0.6	3.1±0.8	0.036
	末次随访	1.0±0.3	1.1±0.4	0.161
	P 值	<0.001	<0.001	
HHS 评分 (分)	术前	54.4±6.2	53.8±7.0	0.651
	术后 3 个月	76.7±5.6	72.4±6.5	<0.001
	末次随访	87.2±5.0	85.3±6.0	0.089
	P 值	<0.001	<0.001	
iHOT-33 评分 (分)	术前	43.4±5.8	44.0±6.7	0.633
	术后 3 个月	64.8±6.0	60.5±5.6	<0.001
	末次随访	75.4±7.3	71.8±6.4	0.010
	P 值	<0.001	<0.001	
髋伸-屈 ROM (°)	术前	84.8±4.5	85.0±5.0	0.834
	术后 6 个月	95.0±5.6	94.2±5.3	0.465
	术后 24 个月	104.7±6.2	103.2±6.0	0.222
	P 值	<0.001	<0.001	
髋内-外旋 ROM (°)	术前	30.8±2.3	31.0±2.5	0.678
	术后 6 个月	43.0±1.2	42.5±1.6	0.080
	术后 24 个月	43.5±1.3	43.2±1.4	0.270
	P 值	<0.001	<0.001	

表 4. 两组患者影像资料与比较
Table 4. Imaging data and comparison between the two groups

指标	时间点	开窗组 (n=50)	髓芯组 (n=50)	P 值
ARCO 分级 (例, I/II/III/IV)	术前	0/30/20/0	0/28/22/0	0.687
	术后 6 个月	0/28/22/0	0/26/24/0	0.690
	术后 24 个月	0/20/29/1	0/18/30/2	0.608
	P 值	0.089	0.071	
病灶 (例, <15/15~30/>30)	术前	7/19/24	8/20/22	0.674
	术后 6 个月	12/23/15	10/22/18	0.495
	术后 24 个月	20/25/5	16/26/8	0.304
	P 值	<0.001	0.008	
关节积液征象 (例, -/1+/2+/3+)	术前	0/10/23/17	0/12/25/13	0.399
	术后 6 个月	7/18/20/5	5/18/23/4	0.709
	术后 24 个月	9/21/17/3	8/20/19/3	0.697
	P 值	<0.001	<0.001	
Tönnis 分期 (例, 0/1/2/3)	术前	42/7/1/0	44/6/0/0	0.544
	术后 6 个月	43/7/0/0	44/6/0/0	0.767
	术后 24 个月	43/7/0/0	43/7/0/0	<i>ns</i>
	P 值	0.934	0.942	

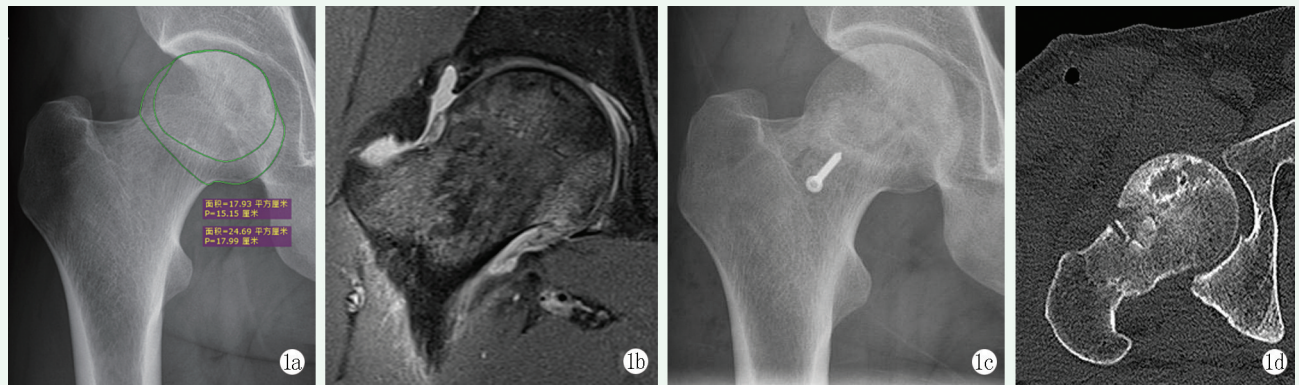


图 1. 患者男性, 40 岁。1a: 术前骨盆正位 X 线片示右侧股骨头坏死, 未见股骨头塌陷, Tönnis 分级 0 级; 1b: 术前 MRI 可见 T2 像下股骨头坏死区域呈混杂信号改变, 符合 ARCO IIC 期; 1c: 开窗植骨术后末次随访 X 线片见螺钉位置良好, 无断裂、移位; 1d: 末次随访 CT 可见股骨头形状圆滑无塌陷。

Figure 1. A 40-year-old male. 1a: Preoperative anteroposterior pelvic X-ray showed necrosis of the right femoral head without collapse of the femoral head, with Tönnis grade of 0; 1b: The preoperative MRI showed mixed signal changes in the necrotic area of the femoral head on T2 image, which was consistent with the ARCO IIC stage; 1c: X-ray at the latest follow-up showed the screw for fenestration fixation in good position without fracture or displacement; 1d: CT at the latest follow-up showed smooth shape of femoral head without collapse.

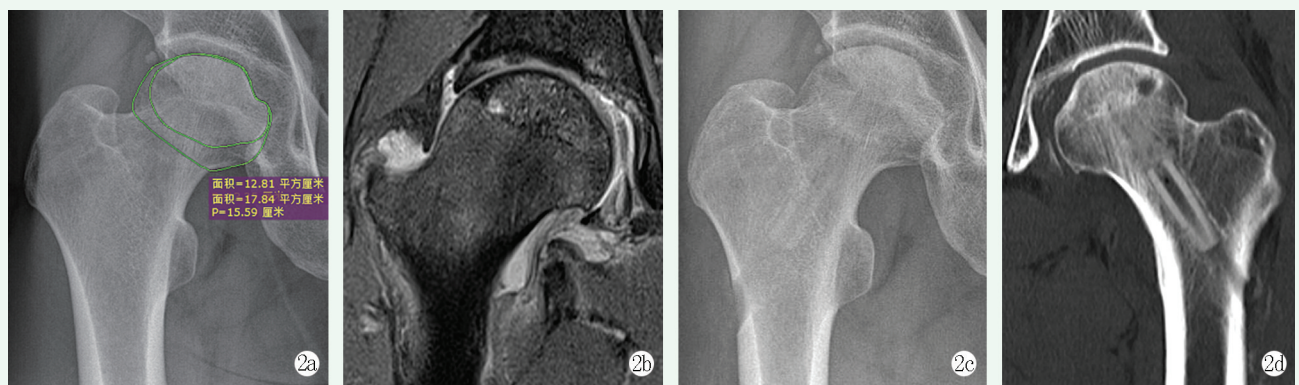


图 2. 患者男性, 38 岁。2a: 术前 X 线片示右侧股骨头形状规则圆滑, 未见股骨头塌陷, Tönnis 分级 I 级; 2b: 术前 MRI 可见 T2 像下股骨头坏死区域呈混杂信号改变, 符合股骨头坏死 ARCO IIC 期; 2c: 髓芯压着植骨后末次随访 X 线片未见股骨头塌陷, 骨隧道及重建棒影; 2d: 末次随访 CT 可见股骨头形状圆滑无塌陷。

Figure 2. A 38-year-old male. 2a: Preoperative X-ray showed regular and smooth shape of the right femoral head, with no collapse of the femoral head, and Tönnis grade of I; 2b: The preoperative MRI showed mixed signal changes in the necrotic area of the femoral head on T2 image, which was consistent with the ARCO IIC stage of femoral head necrosis; 2c: There was no femoral head collapse, bone tunnel and reconstruction rod shadow on the last follow-up X-ray after core compression and bone grafting; 2d: CT of the last follow-up showed smooth shape of the femoral head without collapse.

3 讨论

THA 并非中青年 ONFH 手术首选, 基本于晚期才考虑^[11]。对保髋手术来说, 将坏死骨清理干净, 可恢复血供, 便于病灶成骨修复, 预防或改善部分局部塌陷, 恢复患者股骨头正常形态, 可提供有效力学支撑, 避免负重造成或加重塌陷^[12, 13]。

本研究中, 相比髓芯组, 开窗组手术时间、切口总长度及术中失血量虽然大, 但其植骨量、住院时间显著少, 术后下地行走时间、完全负重活动时间显著早。认为股骨头-颈交界开窗减压打压植骨术虽然操

作复杂, 创伤相对大, 但能减少植骨量, 术后恢复快。究其原因: 开窗减压打压植骨术选择 DAA 入路, 术野显露有限, 操作有一定的难度, 进而增加手术时间; DAA 入路经由肌间隙进入, 不破坏股骨头供血的主要血管, 不影响其血供, 且前侧关节囊切开能充分减压, 改善股骨头血供^[14], 有利于术后骨愈合, 缩短其负重活动时间。白哲等^[15]研究显示, 相比股骨头颈开窗打压植骨术, 早中期 ONFH 患者微创髓芯减压打压植骨术在术后 1 年 VAS 评分、HHS 评分改善上有明显优势, 而两组保髋成功率对比无显著差异。本研究中, 开窗组术后 3 个月 VAS 评分比髓芯组显著低, HHS 评分、iHOT-33 评分均比髓芯

组显著高,认为股骨头-颈交界开窗减压相比股骨头髓芯减压打压植骨治疗后短中期在减轻中青年 IIC、IIIA 期 ONFH 患者疼痛、改善其髋关节功能上有明显优势,与上述报道不符,这可能是由于本研究对象均为 IIC、IIIA 期,而白哲等^[15]研究中 IIC、IIIA 期仅占 47.7%,其余均为 IIB 期,髓芯减压术用于 AR-CO \leq II 期、塌陷面积小者效果明确^[16, 17],但其对晚期 ONFH 的治疗效果尚有争议,且近年来髓芯减压术联合骨髓自体干细胞移植术等联合术式成为热点,相比单纯髓芯减压术能进一步改善早期 ONFH 患者 HHS 评分、延缓塌陷发生^[18]。而股骨头-颈交界开窗减压打压植骨通过机械支撑,将坏死骨完全清理,有利于血供恢复及成骨,同时该术式对髋关节结构无影响,对日后翻修 THA 等处理也影响不大。徐鑫等^[19]研究发现,股骨头-颈交界开窗减压打压植骨术治疗 IIC 期 ONFH 的临床生存率可能更高,但需进一步证实。对 IIIA 期患者选择何种术式的相关报道目前尚少。本研究显示,两组的影像效果相当。另外开窗组末次随访时股骨头生存率高于髓芯组(84.0% vs 74.0%),虽然无显著差异(可能与样本量少有关),但亦提示开窗组治疗保髋成功率更高。究其原因:该术式不仅能直视下将坏死骨彻底清理,而且减压充分;硬化骨钻孔可促进局部血运恢复,同时自体髂骨松质骨植入不存在排斥反应,有利于成骨且不影响骨愈合^[20];打压夯实便于清创后病灶骨修复及重建,有一定的生物力学支撑作用^[14, 21]。

综上所述,相比股骨头髓芯减压打压植骨重建棒置入术,股骨头-颈交界开窗减压打压植骨治疗中青年 IIC、IIIA 期 ONFH 虽耗时,但其在促进患者更早下地行走、缩短完全负重活动时间、术后 3 个月髋关节功能恢复上有优势。由于本研究为回顾性分析,样本量、随访时间受限可能对结果造成一定的偏倚,对此需日后扩大样本量,并行前瞻性研究进一步探索。

利益冲突声明 所有作者声明无利益冲突

作者贡献声明 查杨晓志:课题设计、实施和论文写作、采集分析和解释数据、统计分析、论文审阅;陈雁雄:课题实施、数据采集、统计分析、论文审阅;张俊:课题实施、数据采集、论文审阅及指导,获取研究经费;连星烨:课题实施、采集分析和解释数据、统计分析、论文审阅及指导;孟增东:课题设计、实施及指导、论文写作、分析和解释数据、统计分析、获取研究经费及行政、技术或材料支持及支持性贡献。

参考文献

[1] Rodríguez-Olivas AO, Hernández-Zamora E, Reyes-Maldonado E. Legg-Calve-Perthes disease: overview [J]. Orphanet J Rare

Dis, 2022, 17 (1): 125. DOI: 10.1186/s13023-022-02275-z.

- [2] 郭发启, 高彦军, 邓敏. 2008-2018 年中国股骨头缺血性坏死及其保髋治疗研究现状刊文分析 [J]. 中国骨与关节损伤杂志, 2021, 36 (12): 1342-1344. DOI: 10.7531/j.issn.1672-9935.2021.12.039.
- Guo FQ, Gao YJ, Deng M. Current status of avascular necrosis of the femoral head and its treatment for hip preservation in China from 2008 to 2018 [J]. Chinese Journal of Bone and Joint Injury, 2021, 36 (12): 1342-1344. DOI: 10.7531/j.issn.1672-9935.2021.12.039.
- [3] Karampinas P, Galanis A, Papagrigorakis E, et al. Osteonecrosis of the femoral head. Optimizing the early-stage joint-preserving surgical treatment [J]. Maedica (Bucur), 2022, 17 (4): 948-954. DOI: 10.26574/maedica.2022.17.4.948.
- [4] 孙强, 郭晓忠, 岳聚安, 等. 探索国际骨微循环协会分型对早期股骨头坏死治疗的指导意义 [J]. 中华骨与关节外科杂志, 2023, 16 (12): 1062-1067. DOI: 10.3969/j.issn.2095-9958.2023.12.02.
- Sun Q, Guo XZ, Yue JA, et al. Exploring the guiding significance of Association Research Circulation Osseous staging in the treatment of early-stage osteonecrosis of the femoral head [J]. Chinese Journal of Bone and Joint Surgery, 2023, 16 (12): 1062-1067. DOI: 10.3969/j.issn.2095-9958.2023.12.02.
- [5] Mont MA, Salem HS, Piuze NS, et al. Nontraumatic osteonecrosis of the femoral head: where do we stand today? A 5-year update [J]. J Bone Joint Surg Am, 2020, 102 (12): 1084-1099. DOI: 10.2106/JBJS.19.01271.
- [6] 胡银, 王杨, 周才盛, 等. 两种保髋手术治疗成人股骨头坏死初步结果比较 [J]. 中国矫形外科杂志, 2021, 29 (21): 2005-2008. DOI: 10.3977/j.issn.1005-8478.2021.21.20.
- Hu K, Wang Y, Zhou CS, et al. Comparison of preliminary results of two kinds of hip saving surgery for adult femoral head necrosis [J]. Orthopedic Journal of China, 2021, 29 (21): 2005-2008. DOI: 10.3977/j.issn.1005-8478.2021.21.20.
- [7] 张建, 董跃福, 何维栋, 等. 两种保髋手术治疗股骨头坏死的短期疗效比较 [J]. 中国矫形外科杂志, 2021, 29 (3): 224-228. DOI: 10.3977/j.issn.1005-8478.2021.03.08.
- Zhang J, Dong YF, He WD, et al. Comparison of two hip-preservation procedures for CJFH type L₂ femoral head necrosis [J]. Orthopedic Journal of China, 2021, 29 (3): 224-228. DOI: 10.3977/j.issn.1005-8478.2021.03.08.
- [8] Faiz KW. VAS-visual analog scale [J]. Tidsskr Nor Laegeforen, 2014, 134 (3): 323. DOI: 10.4045/tidsskr.13.1145.
- [9] Nilsson A, Bremander A. Measures of hip function and symptoms: Harris Hip Score (HHS), Hip Disability and Osteoarthritis Outcome Score (HOOS), Oxford Hip Score (OHS), Lequesne Index of Severity for Osteoarthritis of the Hip (LISOH), and American Academy of Orthopedic Surgeons (AAOS) Hip and Knee Questionnaire [J]. Arthritis Care Res (Hoboken), 2011, 63 (Suppl 11): S200-S207. DOI: 10.1002/acr.20549.
- [10] Mohtadi NG, Griffin DR, Pedersen ME, et al. The development and

- validation of a self-administered quality-of-life outcome measure for young, active patients with symptomatic hip disease: the International Hip Outcome Tool (iHOT-33) [J]. *Arthroscopy*, 2012, 28 (5): 595-605. DOI: 10.1016/j.arthro.2012.03.013.
- [11] Liu P, Mu XH, Yu HC, et al. High failure rate after Beta-tricalcium phosphate grafting for the treatment of femoral head osteonecrosis: a retrospective analysis [J]. *BMC Musculoskelet Disord*, 2020, 21 (1): 271. DOI: 10.1186/s12891-020-03291-5.
- [12] 李扬, 陈晓东. 股骨头坏死的保髋治疗 [J]. *临床外科杂志*, 2023, 31 (4): 304-307. DOI: 10.3969/j.issn.1005-6483.2023.04.002.
- Li Y, Chen XD. Hip preservation therapy for femoral head necrosis [J]. *Journal of Clinical Surgery*, 2023, 31 (4): 304-307. DOI: 10.3969/j.issn.1005-6483.2023.04.002.
- [13] 宋晓阳, 张浩强, 乔永杰, 等. 中青年早期股骨头坏死的保髋治疗方法研究进展 [J]. *中华创伤杂志*, 2023, 39 (2): 171-177. DOI: 10.3760/cma.j.cn501098-20220728-00524.
- Song XY, Zhang HQ, Qiao YJ, et al. Research progress in hip-preserving modalities for early osteonecrosis of the femoral head in young and middle-aged patients [J]. *Chinese Journal of Trauma*, 2023, 39 (2): 171-177. DOI: 10.3760/cma.j.cn501098-20220728-00524.
- [14] 刘国杰, 刘沛, 孙永强, 等. 两种入路"电灯泡"术治疗股骨头坏死比较 [J]. *中国矫形外科杂志*, 2022, 30 (3): 208-213. DOI: 10.3977/j.issn.1005-8478.2022.03.04.
- Liu GJ, Liu P, Sun YQ, et al. Comparison of two approaches for lightbulb procedure in the treatment of femoral head necrosis [J]. *Orthopedic Journal of China*, 2022, 30 (3): 208-213. DOI: 10.3977/j.issn.1005-8478.2022.03.04.
- [15] 白哲, 王博强, 郭威, 等. 头颈开窗打压植骨术与髓芯减压打压植骨术治疗早中期股骨头坏死的临床效果比较 [J]. *中国临床医生杂志*, 2021, 49 (2): 208-210. DOI: 10.3969/j.issn.2095-8552.2021.02.024.
- Bai Z, Wang BQ, Guo W, et al. Comparison of clinical effects of head and neck window compression and bone grafting with core decompression and bone grafting in the treatment of early and middle stage femoral head necrosis [J]. *Chinese Journal for Clinicians*, 2021, 49 (2): 208-210. DOI: 10.3969/j.issn.2095-8552.2021.02.024.
- [16] Liu Q, Guo W, Li R, et al. Efficacy of various core decompression techniques versus non-operative treatment for osteonecrosis of the femoral head: a systemic review and network meta-analysis of randomized controlled trials [J]. *BMC musculoskelet Disord*, 2021, 22 (1): 948. DOI: 10.1186/s12891-021-04808-2.
- [17] Woerner M, Voelkl K, Bliemel C, et al. Comparison of two joint-preserving treatments for osteonecrosis of the femoral head: core decompression and core decompression with additional cancellous bone grafting [J]. *J Int Med Res*, 2023, 51 (8): 3000605231190453. DOI: 10.1177/03000605231190453.
- [18] Wang SL, Hu YB, Chen H, et al. Efficacy of bone marrow stem cells combined with core decompression in the treatment of osteonecrosis of the femoral head: A PRISMA compliant meta-analysis [J]. *Medicine (Baltimore)*, 2020, 99 (25): e20509. DOI: 10.1097/MD.00000000000020509.
- [19] 徐鑫, 孙伟, 吴鑫杰, 等. 打压植骨与髓芯减压治疗 ARCO II 期非创伤性股骨头坏死的疗效对比 [J]. *中华骨与关节外科杂志*, 2022, 15 (6): 404-410. DOI: 10.3969/j.issn.2095-9958.2022.06.02.
- Xu X, Sun W, Wu XJ, et al. Comparison of core decompression and impacted bone grafting in treating ARCO II non-traumatic osteonecrosis of the femoral head [J]. *Chinese Journal of Bone and Joint Surgery*, 2022, 15 (6): 404-410. DOI: 10.3969/j.issn.2095-9958.2022.06.02.
- [20] 盛东, 宋琼, 张庆文, 等. 经髋关节外科脱位入路自体髂骨瓣打压植骨治疗中青年 ARCO II、III 期股骨头缺血性坏死 [J]. *中国骨与关节损伤杂志*, 2021, 36 (2): 153-155. DOI: 10.7531/j.issn.1672-9935.2021.02.012.
- Sheng D, Song Q, Zhang QW, et al. The treatment of avascular necrosis of femoral bone in young and middle-aged patients with ARCO II and III by means of surgical dislocation of hip joint with autogenous iliac bone flap and bone grafting [J]. *Chinese Journal of Bone and Joint Injury*, 2021, 36 (2): 153-155. DOI: 10.7531/j.issn.1672-9935.2021.02.012.
- [21] 倘艳锋, 曹向阳, 岳辰, 等. 围塌陷期股骨头坏死的头颈开窗植骨 [J]. *中国矫形外科杂志*, 2022, 30 (16): 1512-1515. DOI: 10.3977/j.issn.1005-8478.2022.16.15.
- Tang YF, Cao XY, Yue C, et al. Head-neck fenestration bone autografting for pericollapse-stage femur head necrosis [J]. *Orthopedic Journal of China*, 2022, 30 (16): 1512-1515. DOI: 10.3977/j.issn.1005-8478.2022.16.15.

(收稿:2024-05-08 修回:2024-09-05)

(同行评议专家:)

(本文编辑:)