

· 技术创新 ·

开放获取

组合式微创手术治疗胸椎侵袭性血管瘤[△]

韩念荣^a, 田育魁^b, 刘岩路^a, 艾克热木·吾斯曼^a, 黄异飞^a, 胡炜^{a*}

(新疆医科大学附属中医医院, a. 脊柱二科; b. 推拿科, 新疆乌鲁木齐 830000)

摘要: [目的] 介绍组合式微创手术治疗胸椎侵袭性血管瘤的手术技术和初步临床结果。[方法] 患者术前行脊髓动脉造影了解椎管内占位病变供血情况, 并采用弹簧圈栓塞供血动脉。患者俯卧位, 透视定位, 局麻后经皮穿刺沿椎弓根进针到达椎体目标位置, 建立工作通道, 插入一次性使用可弯曲骨水泥填充套件, 反复透视下间断缓慢推入骨水泥, 填充整个病变椎体。局麻后置入椎间孔镜工作通道, 插入环钻将椎间孔扩大成形。将操作套管推入病变椎体后缘, 镜下摘除椎管内占位组织, 并探查硬脊膜搏动情况。留置引流并缝合固定。[结果] 患者术后腰背部疼痛 VAS 评分 0 分, 右下肢肌力恢复至 4 级+。术后 1 周影像显示椎管内血管瘤约 60% 被摘除, 术区渗出明显; 与术后 1 周对比, 术后 4 个月椎管内未完全摘除的血管瘤逐渐皱缩, 未见明显复发增大改变, 受压脊髓明显恢复, 且术区渗出完全吸收。[结论] 组合式微创手术方式为胸椎侵袭性血管瘤的微创治疗方法提供了新思路与技术方法, 初步治疗效果良好。

关键词: 椎体血管瘤, 经皮椎体成形, 椎间孔镜, 微创手术

中图分类号: R738.1 **文献标志码:** A **文章编号:** 1005-8478 (2024) 17-1605-04

Combined minimally invasive surgery for invasive vertebral hemangioma in thoracic spine // HAN Nian-rong^a, TIAN Yu-kui^b, LIU Yan-lu^a, IkeRemu-Wuseman^a, HUANG Yi-fei^a, HU Wei^a. a. Department of Spinal Surgery, b. Department of Massage, Affiliated Hospital of Traditional Chinese Medicine, Xinjiang Medical University, Urumqi 830000, China

Abstract: [Objective] To introduce the surgical technique and preliminary clinical results of combined minimally invasive surgery for the treatment of invasive vertebral hemangioma in the thoracic spine. [Methods] The patients received spinal artery angiography before surgery to understand the blood supply of the lesions in the spinal canal, and the blood supply artery was embolized by spring coil. The patient was placed in prone position with fluoroscopic positioning performed. After local anesthesia, percutaneous puncture needles were inserted along the pedicle to reach the target location of the vertebral body, and then a working channel was established. Disposable flexible bone cement filling kit was inserted, and the bone cement was slowly pushed into the entire lesion area under repeated fluoroscopy. In addition, the transforaminal endoscope working channel was established under local anesthesia, and a trephine was inserted to enlarge and shape the foramina. The operating cannula was pushed into the posterior margin of the involved vertebra, the occupying tissue in the spinal canal was removed under the endoscope until the dural pulsation was observed. Finally, a drainage tube was placed and the wound was sutured. [Results] The patients got significant pain relief with VAS score of 0 postoperatively, while had muscle strength of the right lower limb recovered to grade 4+. Images 1 week after surgery showed about 60% of intraspinal hemangioma removed, with obvious operative area exudation. The remnant of hemangioma shrunk gradually 4 months after surgery compared with that preoperatively, no significant recurrence or increase was observed, the spinal cord recovered significantly under compression, and the operative area exudation was completely absorbed. [Conclusion] This combined minimally invasive surgery provides a new idea and technique of the minimally invasive treatment for invasive vertebral hemangioma in thoracic spine, and achieves satisfactory primary clinical outcome.

Key words: vertebral hemangioma, transforaminal endoscopy, percutaneous vertebroplasty, minimally invasive surgery

椎体血管瘤 (vertebral hemangiomas, VH) 是脊柱最常见的以血管增生为特征的良性肿瘤, 占脊柱病变的 10%~27%^[1]。在 VH 分类系统中^[2], 最严重的一

类是 IV 型 VH, 也被称为侵袭性 VH, 是指少数血管瘤表现为骨扩张和骨外延伸的侵袭性生长, 造成椎体、椎弓根或椎板的膨胀性改变, 引起脊髓压迫, 并

DOI:10.20184/j.cnki.Issn1005-8478.100729

△基金项目:新疆维吾尔自治区自然科学基金-青年科学基金项目(编号:2022D01C815)

作者简介:韩念荣,主治医师,研究方向:中西医结合脊柱外科,(电子信箱)605567562@qq.com

*通信作者:胡炜,(电子信箱)realhuwei@163.com

伴有神经功能受损的临床特征。这种有症状的侵袭性VH主要见于胸椎区域，约占脊柱血管瘤的0.9%~2%^[3-5]。这些良性肿瘤可能被误认为恶性肿瘤骨转移，导致不必要的活体组织检查，这有很高的出血风险^[6]。对于VH患者的治疗可选择介入（栓塞或乙醇注射）、放疗或开放性手术^[7, 8]。但对于IV型VH患者而言，手术是主要的治疗方法，但存在大量出血、病理性骨折、需要再次手术的肿瘤复发及残留以及其他并发症^[9]。本文报告1例T₉椎侵袭性血管瘤患者，行椎间孔镜下椎管占位病变摘除术联合经皮T₉椎体成形术，取得良好临床疗效，现手术技术和初步结果报告如下。

1 手术技术

1.1 术前准备

术前影像检查确定病灶位置（图1a, 1b）。考虑到椎管内占位病变为侵袭性血管瘤可能性，若贸然行手术切除，术中可能发生凶猛出血，需大量备血，故拟定术前行脊髓动脉造影术了解椎管内占位病变血供情况，最终明确椎管内占位病变为T₉侵袭性VH（图1c），后采用弹簧圈栓塞右侧第9肋间后动脉近端（图1d），为后续手术治疗减少出血做充分准备。

1.2 麻醉与体位

患者局部浸润麻醉，协助患者取俯卧位，腹侧为“U”形软垫以保证腹部悬空，双手置于头端。

1.3 手术操作

G形臂X线机透视下，确定病变椎，正侧位像确定T₉椎弓根部位，常规消毒铺巾，沿T₉左侧椎弓根进针，到达椎体目标位置后插入一次性使用经皮穿刺针，在一次性使用经皮穿刺针引导下确立工作通道，插入一次性使用可弯曲骨水泥填充套件，反复透视下间断缓慢推入骨水泥约5.5 ml，术中透视见骨水泥椎体内弥散良好。手术过程未见椎旁及椎管内骨水泥渗漏，拔除工作通道，切口用-氰基丙烯酸正丁酯医用粘合剂粘合并用创可贴包扎。

在T_{9/10}间隙右侧旁开6 cm，沿孔间手术入路，用小号针头实施皮肤和皮下肌肉组织局部麻醉，G形臂透视定位下，在T_{9/10}右侧间隙，将导针沿针孔插入，拔出椎体穿刺针，用环钻将T_{9/10}椎间孔扩大成形。置入工作通道，透视确定工作套管位置良好，连接影像系统并调至影像清晰。将操作套管缓慢推入至T₉椎体后缘（图1e, 1f），可见胸段硬脊膜腹侧淡红色占位组织，用髓核钳轻柔多次取出占位组织，用一次性双

极射频手术电极局部止血，镜下可见硬脊膜搏动良好，右侧留置引流管引流，并予缝合固定，无菌包扎。手术顺利，麻醉效果满意，术中诊断同术前诊断，术中出血量约100 ml，未输血，术后安返病室。

1.4 术后处理

患者手术后给予常规补液抗炎对症处理，术后第1 d可正常饮食，嘱患者开始下床活动锻炼（家属搀扶保护下或扶拐），术后1周脱拐并加大下床行走距离，术后2周可恢复正常行走速度。

2 病例资料

2.1 一般资料

患者，女，58岁，因腰背部疼痛伴双下肢麻木无力半年余于2023年5月1日在当地医院门诊就诊，完善胸椎平扫+增强MRI提示：T₉椎体异常信号，提示血管瘤，平T₉椎体椎管内占位，提示脊膜瘤（图1a）。建议转院行手术治疗，故于2023年5月6日收住本院。患者自诉半年前无明显诱因出现腰背部疼痛，症状不明显，局限于后背中部，伴双下肢麻木无力，下地活动时易摔倒，自觉双足底厚重感明显，尤以右下肢为甚。既往体健，无慢性病史。专科查体：Lovett分级左下肢肌力4级+，右下肢肌力3级+；右侧膝腱反射活跃，右侧跟腱反射活跃，余查体均阴性。疼痛视觉模拟评分（visual analogue scale, VAS）2分（腰背部）。辅助检查：肿瘤标记物均未见异常。本研究经新疆医科大学附属中医医院（新疆维吾尔自治区中医医院）伦理委员会批准（伦理批件号：2023XE0186），将按照世界医学协会赫尔辛基宣言进行，患者已签署知情同意书。

2.2 初步结果

术后患者自诉腰背部疼痛症状消失，VAS评分0分（腰背部），双下肢麻木感较术前明显减轻，查体：Lovett分级左下肢肌力5级，右下肢肌力4级+，右侧膝腱反射正常，右侧跟腱反射正常。

术后1周，胸椎MRI平扫+增强提示椎管内血管瘤约60%被摘除，术区渗出明显（图1g）；与术后1周对比，术后4个月显示椎管内未完全摘除的血管瘤逐渐皱缩，未见明显复发增大改变，受压脊髓明显恢复，且术区渗出完全吸收（图1h）。

3 讨论

在骨骼中，血管瘤起源于胚胎发育异常，也称为

错构瘤病变，具有血管密集、斑块内水肿和斑块内脂肪等特性^[10]。但其具体发病机制尚无定论^[11]。有较多文献报道提及妊娠期发病的侵袭性血管瘤，发病时间主要集中在妊娠的中后期，推测可能与妊娠期血流量变化和分泌促血管生成的相关激素有关^[12, 13]。临床表现上，侵袭性 VH 起病初期多以腰背部疼痛为主，直至椎体内瘤体突破椎体后壁向椎体外形成占位

性生长，椎管内相应神经功能损伤造成双下肢无力、麻木或疼痛等临床表现，出现神经受损的病程长短不一，进展快慢也不同^[14-17]。影像学上，不典型的侵袭性 VH 极易造成误诊，报道显示，仅通过影像学该病被误诊为脊膜瘤、浆细胞瘤、转移性脊柱肿瘤、巨细胞肿瘤等脊柱相关肿瘤^[18]。

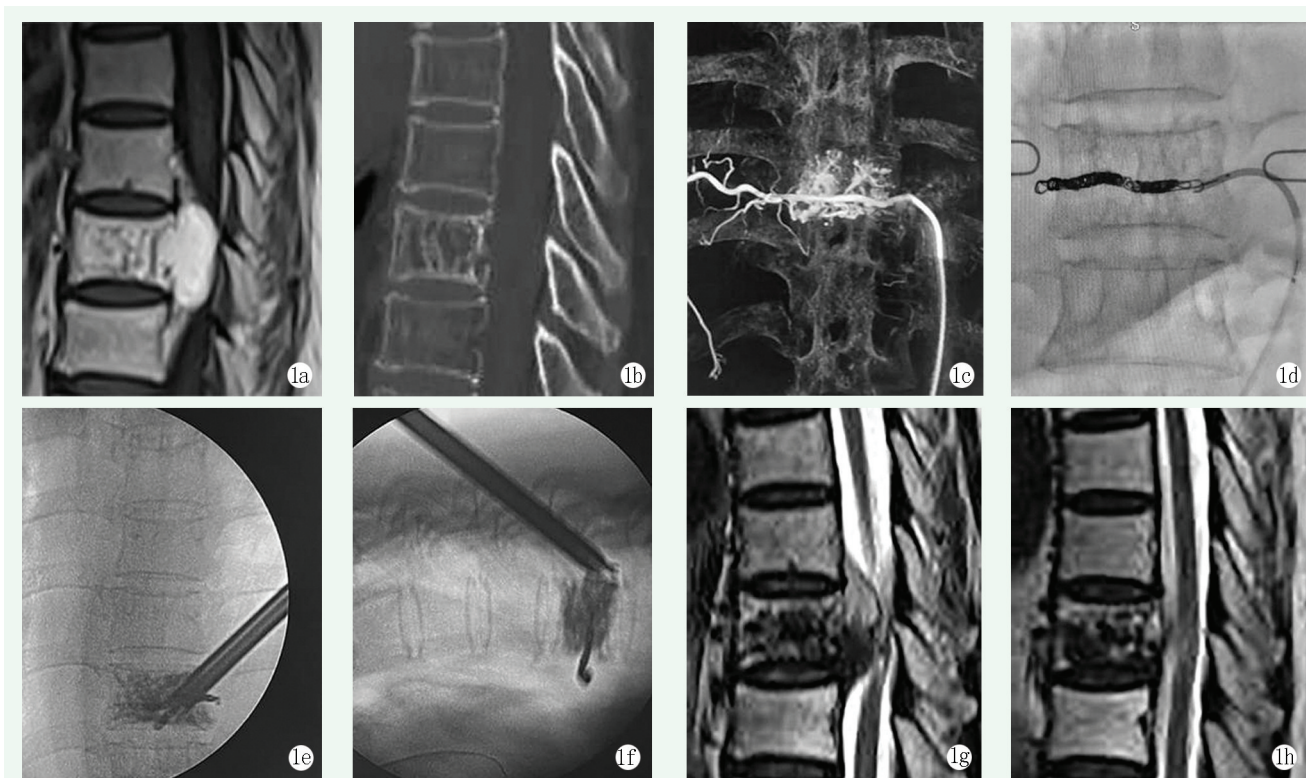


图 1. 患者女性，58 岁。1a: 术前矢状面增强 MRI 显示椎体后方椎管内占位；1b: 术前矢状面 CT 见椎体垂直方向加厚的骨小梁，呈栅栏样；1c: 术前脊髓血管造影冠状位显示 T₉ 椎体内占位，血供来源于右侧第 9 肋间后动脉；1d: 弹簧圈栓塞右侧第 9 肋间后动脉近端；1e: 术中冠状面透视显示 T₉ 椎体骨水泥填充、椎间孔镜已到椎体中线位置；1f: 术中矢状面透视显示 T₉ 椎体后缘椎间孔镜深度和位置；1g: 术后 1 周复查胸椎 MRI 矢状位提示椎管内血管瘤约 60% 被摘除；1h: 术后 4 个月复查胸椎 MRI 矢状位提示椎管内未完全摘除的血管瘤逐渐皱缩，受压脊髓明显恢复。

Figure 1. A 58-year-old female. 1a: Preoperative sagittal enhanced MRI showed a lesion in spinal canal behind the vertebral body; 1b: Preoperative sagittal CT showed thickened vertical bone trabeculae in palisade shape; 1c: Preoperative coronal spinal angiography showed mass in the T₉ vertebra, with blood supply coming from the right 9th posterior intercostal artery; 1d: Embolization of the proximal end of the 9th posterior intercostal artery on the right side by spring coil; 1e: Intraoperative coronal fluoroscopy showed that the T₉ vertebral body was filled with bone cement and the endoscope reached the midline of the vertebral body; 1f: Intraoperative sagittal fluoroscopy showed the depth and position of the endoscope at the posterior margin of the T₉ vertebral body; 1g: 1 week after surgery, MRI sagittal scan showed that about 60% of intraspinal hemangioma was removed; 1h: MRI sagittal scan 4 months after the operation showed that the remnant of hemangioma shrank with the spinal cord decompressed significantly.

综上所述，准确诊断和治疗方式的选择均尤为重要。虽然对于侵袭性 VH 的治疗尚无明确的指导方针，手术总是伴有术中脊髓损伤的风险，有研究报告侵袭性椎体血管瘤复发会导致致残性截瘫。因此，对 VH 患者进行减压和稳定是很重要的^[19]。针对侵袭性 VH 而言，用来检测动脉支线并明确诊断的术前数字减影血管造影是非常必要的^[6]。针对侵袭性 VH 的手术治疗，必须事先进行瘤体供血动脉栓塞，以减少出

血量，否则需大量备血^[20]。本案例中首次将两种微创手术方式组合应用于患者：骨水泥不但能有效降低术中出血量、降低术后肿瘤复发率^[21]，同时能够增加病变椎体的强度；椎间孔镜下椎管占位病变摘除术利用内镜系统，在尽可能少地破坏脊柱后方原稳定结构的前提下摘除椎管内病变，该手术方式具有麻醉风险小（局部麻醉）、创口小、出血少及安全性高等优点，是目前外科手术“精细化、微创化”理念的具体落实，

同时也扩展了椎间孔镜的适用范围。值得指出的是,该病例不论是从患者(症状)还是医生(影像学)的角度看,结局都是令人满意的,这无疑为治疗方式的微创组合方法提供了新思路。

参考文献

- [1] Barzin M, Maleki I. Incidence of vertebral hemangioma on spinal magnetic resonance imaging in Northern Iran [J]. *Pak J Biol Sci*, 2009, 12 (6) : 542-544. DOI: 10.3923/pjbs.2009.542.544.
- [2] Jiang L, Liu XG, Yuan HS, et al. Diagnosis and treatment of vertebral hemangiomas with neurologic deficit: a report of 29 cases and literature review [J]. *Spine J*, 2014, 14 (6) : 944-954. DOI: 10.1016/j.spinee.2013.07.450.
- [3] Schrock WB, Wetzel RJ, Tanner SC, et al. Aggressive hemangioma of the thoracic spine [J]. *J Radiol Case Rep*, 2011, 5 (10) : 7-13. DOI: 10.3941/jrcr.v5i10.828.
- [4] Alexander J, Meir A, Vrodos N, et al. Vertebral hemangioma: an important differential in the evaluation of locally aggressive spinal lesions [J]. *Spine (Phila Pa 1976)*, 2010, 35 (18) : E917-920. DOI: 10.1097/brs.0b013e3181dddb24.
- [5] 李大森, 郭卫, 杨荣利, 等. 脊椎血管瘤的外科治疗策略 [J]. *中国矫形外科杂志*, 2010, 18 (5) : 385-388. DOI: CNKI:SUN:ZJXS.0.2010-05-016.
Li DS, Guo W, Yang RL, et al. Surgical treatment strategies for spinal hemangioma [J]. *Orthopedic Journal of China*, 2010, 18 (5) : 385-388. DOI: CNKI:SUN:ZJXS.0.2010-05-016.
- [6] Pinto DS, Hoisala VR, Gupta P, et al. Aggressive vertebral body hemangioma causing compressive myelopathy - two case reports [J]. *J Orthop Case Rep*, 2017, 7 (2) : 7-10. DOI: 10.13107/jocr.2250-0685.724.
- [7] 彭龙, 赵红卫, 刘扬, 等. 椎体侵袭性血管瘤 1 例 [J]. *中国矫形外科杂志*, 2019, 27 (23) : 2204-2206. DOI: 10.3977/j.issn.1005-8478.2019.23.23.
Peng L, Zhao HW, Liu Y, et al. A case of invasive hemangioma of vertebral body [J]. *Orthopedic Journal of China*, 2019, 27 (23) : 2204-2206. DOI: 10.3977/j.issn.1005-8478.2019.23.23.
- [8] 江仁兵, 徐以春, 白靖平, 等. 症状性椎体血管瘤的诊治策略 [J]. *中国矫形外科杂志*, 2011, 19 (14) : 1207-1209. DOI: 10.3977/j.issn.1005-8478.2011.14.17.
Jiang RB, Xu YC, Bai JP, et al. Diagnosis and treatment of symptomatic vertebral hemangioma [J]. *Orthopedic Journal of China*, 2011, 19 (14) : 1207-1209. DOI: 10.3977/j.issn.1005-8478.2011.14.17.
- [9] Piper K, Zou L, Li D, et al. Surgical management and adjuvant therapy for patients with neurological deficits from vertebral hemangiomas: a meta-analysis [J]. *Spine (Phila Pa 1976)*, 2020, 45 (2) : E99-E110. DOI: 10.1097/BRS.0000000000003181.
- [10] Rodallec MH, Feydy A, Larousserie F, et al. Diagnostic imaging of solitary tumors of the spine: what to do and say [J]. *Radiographics*, 2008, 28 (4) : 1019-1041. DOI: 10.1148/rg.284075156.
- [11] Slon V, Stein D, Cohen H, et al. Vertebral hemangiomas: their demographical characteristics, location along the spine and position within the vertebral body [J]. *Eur Spine J*, 2015, 24 (10) : 2189-2195. DOI: 10.1007/s00586-015-4022-y.
- [12] 王奔, 翟书珩, 姜亮, 等. 脊柱侵袭性血管瘤的诊断与治疗研究进展 [J]. *中国脊柱脊髓杂志*, 2022, 32 (2) : 184-188. DOI: 10.3969/j.issn.1004-406X.2022.02.13.
Wang B, Zhai SH, Jiang L, et al. Advances in diagnosis and treatment of invasive hemangioma of spine [J]. *Chinese Journal of Spine and Spinal Cord*, 2022, 32 (2) : 184-188. DOI: 10.3969/j.issn.1004-406X.2022.02.13.
- [13] Sewell MD, Dbeis R, Bliss P, et al. Radiotherapy for acute, high-grade spinal cord compression caused by vertebral hemangioma [J]. *Spine J*, 2016, 16 (3) : e195-196. DOI: 10.1016/j.spinee.2015.10.018.
- [14] Chandra SP, Singh P, Kumar R, et al. Long-term outcome of treatment of vertebral body hemangiomas with direct ethanol injection and short-segment stabilization [J]. *Spine J*, 2019, 19 (1) : 131-143. DOI: 10.1016/j.spinee.2018.05.015.
- [15] Wang B, Meng N, Zhuang H, et al. The role of radiotherapy and surgery in the management of aggressive vertebral hemangioma: a retrospective study of 20 patients [J]. *Med Sci Monit*, 2018, 24: 6840-6850. DOI: 10.12659/MSM.910439.
- [16] Wang B, Jiang L, Wei F, et al. Progression of aggressive vertebral hemangiomas during pregnancy: Three case reports and literature review [J]. *Medicine (Baltimore)*, 2018, 97 (40) : e12724. DOI: 10.1097/MD.00000000000012724.
- [17] Vasudeva VS, Chi JH, Groff MW. Surgical treatment of aggressive vertebral hemangiomas [J]. *Neurosurg Focus*, 2016, 41 (2) : E7. DOI: 10.3171/2016.5.focus16169.
- [18] Wang B, Zhang L, Yang S, et al. Atypical radiographic features of aggressive vertebral hemangiomas [J]. *J Bone Joint Surg Am*, 2019, 101 (11) : 979-986. DOI: 10.3171/2016.5.FOCUS16169.
- [19] Gala RB, Dhar SB, Kale SY, et al. Aggressive vertebral hemangioma causing recurring myelopathy - a rare case report and review of literature [J]. *J Orthop Case Rep*, 2021, 11 (6) : 19-22. DOI: 10.13107/jocr.2021.v11.i06.2240.
- [20] Goldstein CL, Varga PP, Gokaslan ZL, et al. Spinal hemangiomas: results of surgical management for local recurrence and mortality in a multicenter study [J]. *Spine (Phila Pa 1976)*, 2015, 40 (9) : 656-664. DOI: 10.1097/BRS.0000000000000840.
- [21] Wang B, Han SB, Jiang L, et al. Intraoperative vertebroplasty during surgical decompression and instrumentation for aggressive vertebral hemangiomas: a retrospective study of 39 patients and review of the literature [J]. *Spine J*, 2018, 18 (7) : 1128-1135. DOI: 10.1016/j.spinee.2017.11.003.

(收稿:2023-10-17 修回:2024-04-31)
(同行评议专家:李世梁, 付存磊)
(本文编辑:郭秀婷)