

· 临床研究 ·

单侧双通道内镜治疗脱垂游离型腰椎间盘突出症

李冬月, 苏庆军, 张希诺, 陶鲁铭, 海涌*

(首都医科大学附属北京朝阳医院骨科, 北京 100020)

摘要: [目的] 探讨单侧双通道内镜 (unilateral biportal endoscopy, UBE) 治疗脱垂游离型腰椎间盘突出症 (sequestered lumbar disc herniation, SLDH) 的安全性和临床疗效。[方法] 回顾性分析 2020 年 7 月—2021 年 10 月应用 UBE 治疗的 27 例 SLDH 患者的临床资料。均采用俯卧位全麻下 UBE 摘除脱垂游离的髓核组织, 评价临床及影像结果。[结果] 27 例患者均顺利完成手术, 手术时间平均 (88.5±12.8) min, 术中均未发生血管、神经损伤、类脊髓高压反应等相关并发症, 硬脊膜撕裂 1 例。随访时间平均 (19.2±4.0) 个月。随着术前、术后 6 个月和末次随访的时间推移, 腰痛 VAS 评分 [(3.2±1.8), (0.8±0.5), (0.2±0.2), $P<0.001$]、腿痛 VAS 评分 [(7.8±1.1), (1.0±0.4), (0.4±0.4), $P<0.001$] 和 ODI 评分 [(74.4±5.3), (17.8±1.3), (10.7±1.3), $P<0.001$] 显著减少, JOA 评分 [(14.5±2.7), (22.6±3.1), (25.9±2.8), $P<0.001$] 显著增加。至末次随访时, 复发 1 例, 按改良 MacNab 疗效评定标准优良率 96.3%。影像学方面, 随时间推移椎管占位率 [(56.4±13.3)%, (8.9±3.0)%, (8.9±3.0)%, $P<0.001$] 显著下降, 手术节段椎间隙高度和腰椎前凸角无明显变化 ($P>0.05$)。[结论] 单侧双通道内镜治疗脱垂游离型腰椎间盘突出症安全有效, 临床效果满意。

关键词: 单侧双通道内镜, 椎间盘切除术, 脱垂游离型腰椎间盘突出症

中图分类号: R681.53 **文献标志码:** A **文章编号:** 1005-8478 (2024) 05-0459-04

Unilateral biportal endoscopy for sequestered lumbar disc herniation // Li Dong-yue, SU Qing-jun, ZHANG Xi-nuo, TAO Lu-ming, HAI Yong. Department of Orthopaedics, Beijing Chaoyang Hospital, Capital Medical University, Beijing 100020, China

Abstract: [Objective] To evaluate the safety and clinical efficacy of unilateral biportal endoscopy (UBE) for sequestered lumbar disc herniation (SLDH). **[Methods]** A retrospective study was conducted on 27 patients who received endoscopic discectomy of SLDH from July 2020 to October 2021. All the patients had the prolapsed free nucleus pulposus tissue removed by UBE under general anesthesia in prone position, and the clinical and imaging results were evaluated. **[Results]** All the 27 patients were operated successfully, with the average operation time of (88.5±12.8) min, with no vascular, nerve injury, spinal hyperbaric reaction and other related complications occurred during the operation, despite of dural tear in a case. As time went from that preoperative to 6 months postoperatively and the last follow-up, which was lasted for the average of (19.2±4.0) months, the VAS score for the low back pain [(3.2±1.8), (0.8±0.5), (0.2±0.2), $P<0.001$], VAS score for leg pain [(7.8±1.1), (1.0±0.4), (0.4±0.4), $P<0.001$] and ODI scores [(74.4±5.3), (17.8±1.3), (10.7±1.3), $P<0.001$] significantly reduced, whereas the JOA score significantly increased [(14.5±2.7), (22.6±3.1), (25.9±2.8), $P<0.001$]. At the last follow-up, only one patient got recurrence, and the excellent rate of clinical outcome was 96.3% based on the modified MacNab's criteria. As for imaging, the spinal canal occupied rate decreased significantly over time [(56.4±13.3)%, (8.9±3.0)%, (8.9±3.0)%, $P<0.001$], while the disc height and lumbar lordotic angle of the involved level remained unchanged significantly ($P>0.05$). **[Conclusion]** The unilateral biportal endoscopy is safe and effective in the treatment of sequestered lumbar disc herniation, and achieves satisfactory clinical outcomes.

Key words: unilateral biportal endoscopy, discectomy, sequestered lumbar disc herniation

当腰椎间盘突出髓核离开椎间盘水平向上或向下游离到椎管内, 称为脱垂游离型腰椎间盘突出症 (sequestered lumbar disc herniation, SLDH), 常伴有严重的神经症状, 多需手术治疗^[1]。传统开放手术损伤较大, 因此脊柱内镜手术更多的被选择^[2-4]。椎间孔镜技术 (percutaneous endoscopic lumbar discectomy, PELD) 视

野相对固定, 骨性结构产生较大阻挡, 探查脱垂游离的髓核比较困难^[2, 3], 游离髓核的完全摘除以及神经根的满意探查具有较大挑战性。单侧双通道内镜技术 (unilateral biportal endoscopy, UBE) 的操作通道可应用脊柱外科常规减压工具, 向上或向下切除部分椎板, 获得满意的手术视野, 有利于对椎管内向上或向

DOI:10.3977/j.issn.1005-8478.2024.05.14

作者简介: 李冬月, 副主任医师, 研究方向: 脊柱外科, (电话)15201303694, (电子信箱)pku_ldy@126.com

* 通信作者: 海涌, (电话)010-85231229, (电子信箱)prof_haiyong@126.com

下脱垂游离的髓核进行探查并取出,更好地显露神经根,达到确切的减压效果^[4]。现回顾性分析2020年7月—2021年10月本科采用UBE治疗的27例SLDH,探讨其安全性和临床疗效。

1 临床资料

1.1 一般资料

回顾性分析2020年7月—2021年10月本科收治27例的SLDH患者的临床资料。患者影像学均提示为脱垂游离型腰椎间盘突出,影像学表现与临床症状相符,临床症状主要由单一节段引起,下肢症状严重。排除单纯腰椎间盘突出及无脱垂游离、伴有腰椎滑脱、退变性侧凸或脊柱不稳者,或既往有腰椎手术病史及患有腰椎结核、肿瘤等疾病者。其中男15例,女12例。年龄18~63岁,平均(39.9±12.2)岁。22例伴/5例不伴腰痛。体格检查提示下肢出现相应神经根受损的感觉、肌力及反射改变,术前保守治疗4~21 d,均无明显改善。21例髓核向尾侧脱出,6例向头侧脱出,其中L_{4/5}节段17例,L_{5/S₁}节段10例。本研究经医院伦理委员会批准,所有患者均知情同意。

1.2 手术方法

均采用俯卧位全麻下UBE摘除脱垂游离的髓核组织。全麻后,透视确认责任间隙,以上位椎体棘突根部为中心,旁开中线1.5~2.0 cm,上下距离为1.5 cm各做一纵行切口。近端为观察通道切口,长约0.4 cm,置入脊柱内镜。远端为工作通道切口,长约1.0 cm,置入操作器械,穿过椎旁肌到达上位椎体棘突根部。打开灌注系统(保持冲洗液平面高于手术切口平面40~50 cm),用等离子射频电刀分离椎板和黄韧带上的软组织,去除部分椎板边缘、下关节突内侧部分,显露黄韧带并去除,显露硬膜囊,向外侧切除部分上关节突内侧缘,显露神经根。依据术前影像学提示的髓核脱垂游离方向探查椎管,根据需要扩大开窗,注意保护关节突关节结构,避免过度切除,破坏脊柱的稳定结构。找到脱垂游离的髓核后,利用神经剥离子分离其与周围组织的粘连,用L形神经拉钩牵开硬膜囊或神经根后,摘除游离的髓核组织。探查神经根全长无受压,松弛无张力,硬膜囊恢复正常搏动,确切止血后,撤出器械和内镜。排出残留冲洗液,缝合伤口。

1.3 评价指标

记录围手术期资料,采用疼痛视觉模拟评分(visual analogue scale, VAS)、Oswestry功能障碍指数

(Oswestry disability index, ODI)、日本骨科协会(Japanese Orthopaedic Association, JOA)评分和改良MacNab标准评价临床效果。行影像学检查,记录椎间隙高度、椎管占位率^[5]以及腰椎前凸角。

1.4 统计学方法

采用SPSS 19.0软件进行统计学分析。计量数据以 $\bar{x} \pm s$ 表示,资料呈正态分布时采用单因素方差分析,两两比较采用LSD法,资料呈非正态分布时,采用秩和检验。等级资料采用Kendall检验。 $P < 0.05$ 为差异有统计学意义。

2 结果

2.1 临床结果

所有患者均顺利完成手术。手术时间69~115 min,平均(88.5±12.8) min,估计出血量<50 ml。术中透视次数为4~7次,平均(5.5±0.9)次,术中均未发生血管、神经损伤、类脊髓高压反应等相关并发症。发生硬膜囊撕裂1例,裂口较小,术中未予缝合,患者术后出现头疼、头晕等脑脊液漏症状,术后第3 d引流液清亮后拔除引流管,伤口缝合后局部加压包扎,经对症处理,5 d后头疼症状明显缓解。所有患者手术切口均一期愈合,无感染病例。

所有患者获得12~27个月随访,平均随访时间(19.2±4.0)个月。随访过程中,1例L_{5/S₁}患者术后3个月复查腰椎MRI时,影像学发现椎间盘再次突出,患者仅剧烈活动后出现轻度下肢麻木,对日常生活影响较小,予以对症保守治疗,目前仍在随访观察。27例患者临床结果见表1。随时间推移,患者腰痛、腿痛VAS评分和ODI评分显著减少($P < 0.05$),JOA评分显著增加($P < 0.05$)。至末次随访时,按改良MacNab疗效评定标准,优24例,良2例,可1例,优良率96.3%。典型病例见图1。

2.2 影像评估

27例患者影像评估结果见表1,与术前相比,术后手术节段椎间隙高度、腰椎前凸角无显著变化($P > 0.05$),术后3个月椎管占位率明显下降($P < 0.05$)。

3 讨论

SLDH患者一般临床症状均较重,下肢放射性疼痛多较为严重,保守治疗效果差,多需要手术治疗^[1]。此类型患者的手术方法包括后路腰椎减压固定融合术、椎板开窗髓核摘除术、PELD、UBE等^[2-4, 6, 7]。

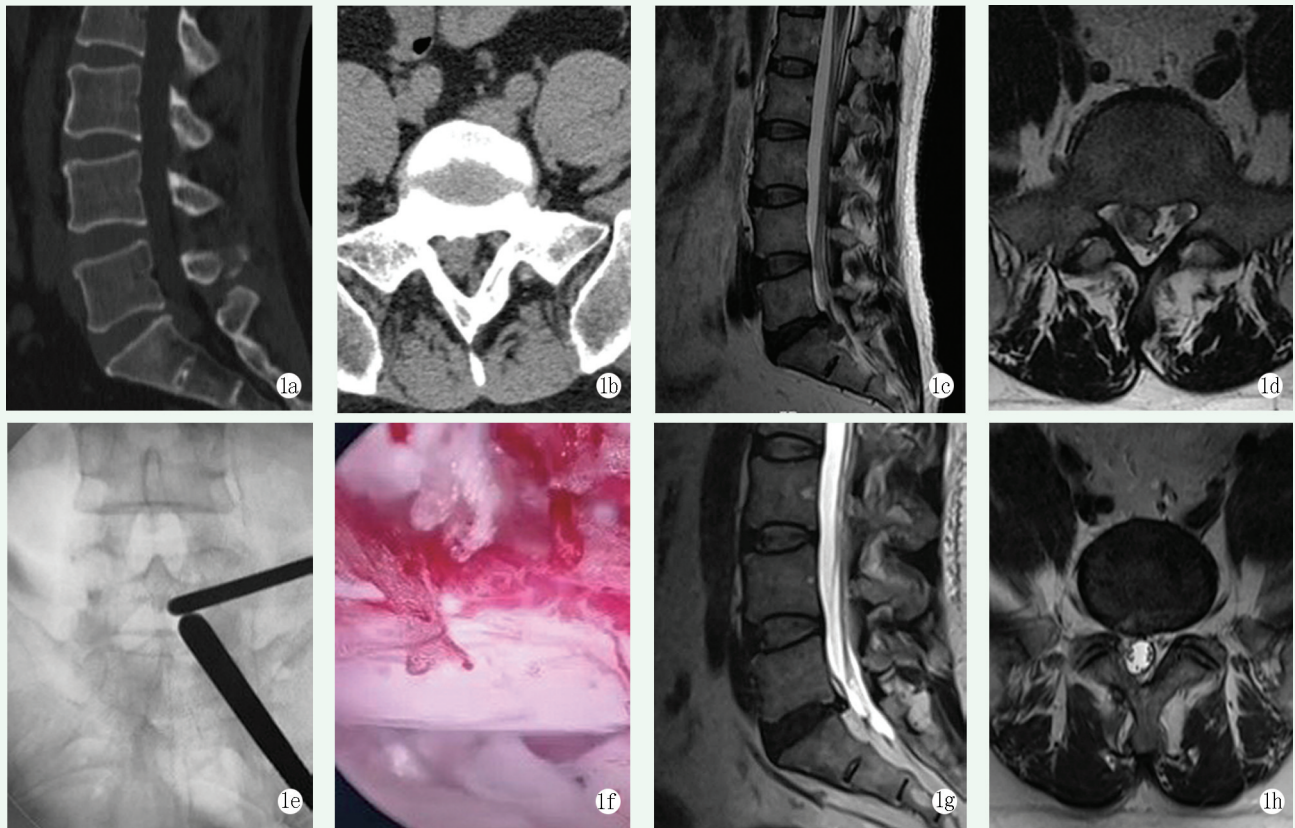


图 1 患者,男,48 岁,诊断为 SLDH,手术方式为 UBE。1a, 1b: 术前 CT 提示 L₅S₁ 椎间盘右侧脱垂并向下游离,无明显钙化; 1c, 1d: 术前 MRI 提示 L₅S₁ 右侧脱垂且向下游离的髓核组织侵占椎管,压迫右侧 S₁ 神经根; 1e: 术中透视定位建立操作通道; 1f: 术中切除脱垂的髓核组织后,探查神经根减压充分; 1g, 1h: 术后 3 个月 MRI 显示 L₅S₁ 右侧脱垂且向下游离的髓核组织完全切除,神经根无明显受压,椎管占位率较术前明显下降。

Figure 1. A 48-year-old male, diagnosed with SLDH and underwent UBE surgery. 1a, 1b: Preoperative CT showed L₅S₁ disc prolapsed-downward without obvious calcification; 1c, 1d: Preoperative MRI revealed L₅S₁ disc prolapsed to the right side and downward with compression of the right S₁ nerve root; 1e: After intraoperative fluoroscopic positioning, operative portals were established; 1f: After resection of prolapsed nucleus pulposus, the nerve root was sufficiently decompressed; 1g, 1h: MRI 3 months after surgery showed that the L₅S₁ disc sequestration was removed completely, with the nerve root released well and canal occupation ratio reduced.

表 1 27 例患者临床和影像检查资料 ($\bar{x} \pm s$) 与比较

Table 1 Clinical and Radiological examination data and comparison ($\bar{x} \pm s$) of 27 cases

指标	术前	术后 3 个月	末次随访	P 值
腰痛 VAS 评分(分)	3.2±1.8	0.8±0.5	0.2±0.2	<0.001
腿痛 VAS 评分(分)	7.8±1.1	1.0±0.4	0.4±0.4	<0.001
ODI 评分(%)	74.4±5.3	17.8±1.3	10.7±1.3	<0.001
JOA 评分(分)	14.5±2.7	22.6±3.1	25.9±2.8	<0.001
椎间隙高度(mm)	12.2±3.0	11.9±2.8	11.7±2.2	0.089
椎管占位率(%)	56.4±13.3	8.9±3.0	8.9±3.0	<0.001
腰椎前凸角(°)	47.1±9.6	45.4±9.1	46.0±8.9	0.317

UBE 和 PELD 都是常用的治疗腰椎间盘突出症的微创手术方法^[3, 8, 9]。但 PELD 为同轴脊柱内镜,治疗 SLDH 时手术视野和器械操作受通道限制,不利于向近端或远端较大范围的探查椎管和摘除脱垂游离的髓核^[8]。由于高髂嵴、椎弓根、关节突等骨性遮

挡,工作通道放置和调整等操作有一定困难,存在镜下减压不彻底、椎间盘残留的问题,也增加了神经根和硬膜囊损伤的风险^[9]。UBE 治疗 SLDH 时的优势在于应用 2 个通道,各自相互独立,互不干扰,具有较高灵活性和操作空间^[10-15]。由于没有管道限制,手术视野空间更广阔,通过调整其位置和角度,可以显示椎间隙的近端和远端,寻找脱垂游离的髓核组织。操作通道可使用常规手术减压器械,因无固定通道限制,具有较大幅度的倾斜或摆动,操作范围更加广阔^[10-12],向近端、远端以及对侧等全方位显露并探查椎管内的结构,有利于彻底摘除脱垂游离的髓核,显露神经根全长并彻底松解^[13-15]。

本研究 27 例 SLDH 患者应用 UBE 治疗,术中能够充分显露脱垂的髓核并摘除,显露神经根全长,使神经根得到彻底减压。27 例患者术后临床症状均明显好转,术后 VAS 评分和 ODI 评分显著减少 ($P <$

0.05), JOA 评分显著升高 ($P<0.05$)。随时间推移, VAS 评分和 ODI 评分持续减少 ($P<0.05$), JOA 评分持续升高 ($P<0.05$)。术后优良率 96.3%, 椎管占位率明显下降 ($P<0.05$), 在临床效果和影像学方面均令人满意。手术节段椎间隙高度和腰椎前凸角无明显变化 ($P>0.05$), 提示 UBE 对腰椎的损伤比较小。

综上所述, UBE 在治疗 SLDH 时, 能够提供更为广阔的手术视野和操作空间, 有利于摘除脱垂游离的髓核, 取得满意的临床效果。但本研究为回顾性研究, 且存在病例数较少、随访时间较短等不足, 未来需要通过更多前瞻性、大样本、长期随访研究去补充和证实这一结果。

参考文献

- [1] Riziq AMG, Mohamed FC, Ejlal AB, et al. Effect of spinal decompression therapy and core stabilization exercises in management of lumbar disc prolapse: a single blind randomized controlled trial [J]. *J Back Musculoskeletal Rehabil*, 2020, 33 (2): 225-231. DOI: 10.3233/BMR-171099.
- [2] Sairyo K, Sakai T, Higashino K, et al. Complications of endoscopic lumbar decompression surgery [J]. *Minim Invasive Neurosurg*, 2010, 53 (4): 175-178. DOI: 10.1055/s-0030-1262814.
- [3] Pan MM, Li QF, Li SC, et al. Percutaneous endoscopic lumbar discectomy: Indications and complications [J]. *Pain Physician*, 2020, 23 (1): 49-56.
- [4] Sang SE, Jin HE, Sang HL, et al. Biportal endoscopic lumbar decompression for lumbar disk herniation and spinal canal stenosis: a technical note [J]. *J Neurol Surg A Cent Eur Neurosurg*, 2017, 78 (4): 390-396. DOI: 10.1055/s-0036-1592157.
- [5] Yu PF, Jiang FD, Liu JT, et al. Outcomes of conservative treatment for ruptured lumbar disc herniation [J]. *Acta Orthop Belg*, 2013, 79 (6): 726-730.
- [6] 李冬月, 海涌, 孟祥龙, 等. Topping-off 与融合固定治疗退行性腰椎疾病的临床疗效及邻近节段退变的对比研究 [J]. *中国矫形外科杂志*, 2017, 25 (11): 967-973. DOI: 10.3977/j.issn.1005-8478.2017.11.02.
- Li DY, Hai Y, Meng XL, et al. Topping-off versus fusion for treatment of degenerative lumbar disease: clinical outcomes and influence on adjacent segment degeneration [J]. *Orthopedic Journal of China*, 2017, 25 (11): 967-973. DOI: 10.3977/j.issn.1005-8478.2017.11.02.
- [7] Kim SK, Kang SS, Hong YH, et al. Clinical comparison of unilateral biportal endoscopic technique versus open microdiscectomy for single-level lumbar discectomy: a multicenter, retrospective analysis [J]. *J Orthop Surg Res*, 2018, 13 (1): 22. DOI: 10.1186/s13018-018-0725-1.
- [8] Li X, Han Y, Di Z, et al. Percutaneous endoscopic lumbar discectomy for lumbar disc herniation [J]. *J Clin Neurosci*, 2016, 33 (1): 19-27.
- [9] Jiang HW, Chen CD, Zhan BS, et al. Unilateral biportal endoscopic discectomy versus percutaneous endoscopic lumbar discectomy in the treatment of lumbar disc herniation: a retrospective study [J]. *J Orthop Surg Res*, 2022, 17 (1): 30. DOI: 10.1186/s13018-022-02929-5.
- [10] Ma X, Li WY, Gao SJ, et al. Comparison of unilateral biportal endoscopic discectomy versus percutaneous endoscopic lumbar discectomy for the treatment of lumbar disc herniation: a systematic review and meta-analysis [J]. *Medicine (Baltimore)*, 2022, 101 (39): e30412. DOI: 10.1097/MD.00000000000030612.
- [11] 谷艳超, 李莹, 谢维, 等. 两种内镜腰椎间盘切除术近期结果比较 [J]. *中国矫形外科杂志*, 2021, 29 (23): 2190-2193. DOI: 10.3977/j.issn.1005-8478.2021.23.17.
- Gu YC, Li Y, Xie W, et al. Comparison of short-term clinical outcomes of two endoscopic discectomies [J]. *Orthopedic Journal of China*, 2021, 29 (23): 2190-2193. DOI: 10.3977/j.issn.1005-8478.2021.23.17.
- [12] Kim JE, Choi DJ, Park EJJ, et al. Biportal endoscopic spinal surgery for lumbar spinal stenosis [J]. *Asian Spine J*, 2019, 13 (2): 334-342. DOI: 10.31616/asj.2018.0210.
- [13] Yuan CH, Wen BJ, Lin HK, et al. Clinical analysis of minimally invasive percutaneous treatment of severe lumbar disc herniation with UBE two-channel endoscopy and foraminal single-channel endoscopy technique [J]. *Oxid Med Cell Longev*, 2022, 2022: 9264852. DOI: 10.1155/2022/9264852.
- [14] Chen L, Zhu B, Zhong HZ, et al. The learning curve of unilateral biportal endoscopic (UBE) spinal surgery by CUSUM analysis [J]. *Front Surg*, 2022, 29 (9): 873691. DOI: 10.3389/fsurg.2022.873691.
- [15] Choi KC, Shim HK, Hwang JS, et al. Comparison of surgical invasiveness between microdiscectomy and 3 different endoscopic discectomy techniques for lumbar disc herniation [J]. *World Neurosurg*, 2018, 116: e750-e758. DOI: 10.1016/j.wneu.2018.05.085.

(收稿:2023-01-03 修回:2023-12-28)

(同行评议专家: 王明飞, 张国强, 曾峥, 包贝西)

(本文编辑: 闫承杰)